

AUTOMATED MICROANEURYSM DETECTION AND DIABETIC RETINOPATHY GRADING

¹ Sharvari Patil, ² Dr. M.S. Gaikwad

¹ Sharvari Patil; Dept. of E&TC.; Sinhagad Academy of Engineering Pune; India

² Dr.M.S. Gaikwad; Dept. of E&TC.; Sinhagad Academy of Engineering Pune; India

Abstract: - Diabetic retinopathy is a serious complication of diabetes mellitus and a major cause of blindness worldwide. Microaneurysms are the first clinically observable lesions indicating diabetic retinopathy. We propose an ensemble-based framework to improve microaneurysm detection. Unlike the well-known approach of considering the output of multiple classifiers, we propose a combination of internal components of microaneurysm detectors, namely preprocessing methods and candidate extractors.

Keywords: Diabetic retinopathy.

1. INTRODUCTION

1.1 General Information

To develop an automated diabetic retinopathy screening system, a detection of lesions in digital fundus photographs is needed. Microaneurysms are the first clinical sign of diabetic retinopathy. The number of microaneurysms is used to indicate the severity of the disease. Early micro aneurysm detection can help reduce the incidence of blindness.

Microaneurysm Features

Microaneurysms are the dilation of retinal capillaries. They are round intra-retinal lesions ranging from 10 to 100 micrometers in size and red in color[1]. The cross-section of a microaneurysm exhibits a Gaussian distribution. Fig.1 illustrates examples of different microaneurysms taken from color retinal images. The top part shows their original format while the bottom depicts them in the green channel (so their shape is more visible). Researchers at the European Association for the Study of Diabetes 45th Annual Meeting in Vienna, Austria, reported that an increase in the number of retinal microaneurysms is associated with worse retinopathy prognosis in patients with Type 1 or 2 diabetes[15].




Fig 1: Different Microaneurysm shown on the top while its equivalent green channel on the bottom

Diabetic Retinopathy

Diabetes is a disease that occurs when the pancreas does not secrete enough insulin or the body is unable to process it properly. Insulin is the hormone that regulates the level of sugar (glucose) in the blood. Diabetes can affect children and adults. Patients with diabetes are more likely to develop eye problems such as cataracts and glaucoma, but the disease's affect on the retina is the main threat to vision[2], [3], [7], [8], [13] and [14]. Most patients develop diabetic changes in the retina after approximately 20 years. The effect of diabetes on the eye is called diabetic retinopathy. Over time, diabetes affects the circulatory system of the retina. The earliest phase of the disease is known as background diabetic retinopathy. In this phase, the arteries in the retina become weakened and leak, forming small, dot-like hemorrhages. These leaking vessels often lead to swelling or edema in the retina and decreased vision. The next stage is known as proliferative diabetic retinopathy. In this stage, circulation problems cause areas of the retina to become oxygen-deprived or ischemic. New, fragile, vessels develop as the circulatory system attempts to maintain adequate oxygen levels within the retina. This is called neovascularization. Unfortunately, these delicate vessels hemorrhage easily[5]. Blood may leak into the retina and vitreous, causing spots or floaters, along with decreased vision. In the later phases of the disease, continued abnormal vessel growth and scar tissue may cause serious problems such as retinal detachment and glaucoma.

The effect of diabetic retinopathy on vision varies widely, depending on the stage of the disease. Some common symptoms of diabetic retinopathy are listed below, however, diabetes may cause other eye symptoms[2].

- Blurred vision (this is often linked to blood sugar levels)

- Floaters and flashes
- Sudden loss of vision

Diabetic patients require routine eye examinations so related eye problems can be detected and treated as early as possible. Most diabetic patients are frequently examined by an internist or endocrinologist who in turn works closely with the ophthalmologist. The diagnosis of diabetic retinopathy is made following a detailed examination of the retina with an ophthalmoscope. Most patients with diabetic retinopathy are referred to vitreo-retinal surgeons who specialize in treating this disease. Diabetic retinopathy is treated in many ways depending on the stage of the disease and the specific problem that requires attention. The retinal surgeon relies on several tests to monitor the progression of the disease and to make decisions for the appropriate treatment. These include: fluorescein angiography, retinal photography, and ultrasound imaging of the eye. The abnormal growth of tiny blood vessels and the associated complication of bleeding is one of the most common problems treated by vitreo-retinal surgeons. Laser surgery called pan retinal photocoagulation (PRP) is usually the treatment of choice for this problem. With PRP, the surgeon uses laser to destroy oxygen-deprived retinal tissue outside of the patient's central vision. While this creates blind spots in the peripheral vision, PRP prevents the continued growth of the fragile vessels and seals the leaking ones. The goal of the treatment is to arrest the progression of the disease. Vitrectomy is another surgery commonly needed for diabetic patients who suffer a vitreous hemorrhage (bleeding in the gel-like substance that fills the center of the eye). During a vitrectomy, the retina surgeon carefully removes blood and vitreous from the eye, and replaces it with clear salt solution (saline). At the same time, the surgeon may also gently cut strands of vitreous attached to the retina that create traction and could lead to retinal detachment or tears. Patients with diabetes are at greater risk of developing retinal tears and detachment. Tears are often sealed with laser surgery. Retinal detachment requires surgical treatment to reattach the retina to the back of the eye. The prognosis for visual recovery is dependent on the severity of the detachment.

Classification of Diabetic Retinopathy

Diabetic retinopathy occurs when the blood vessels of the retina in the posterior part of the eye are damaged. Damages due to small vessels would be known as micro vascular disease while damages due to the arteries would be macro vascular disease.

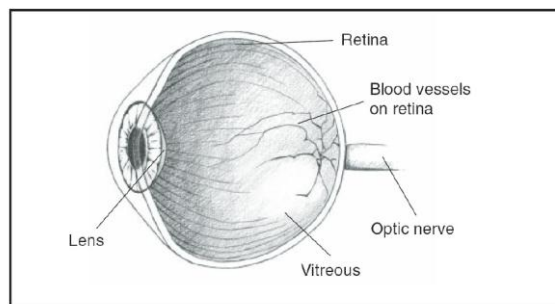


Fig 2 Cross sectional view of human eye

Generally, diabetic retinopathy is classified into two main stages, namely nonproliferative diabetes retinopathy (NPDR) and proliferative diabetes retinopathy (PDR). In NPDR, depending on the presence and extent of the features such as hard exudates, microaneurysms or cotton wools spots due to leakage of fluid and blood from the blood vessels, can be classified to mild, moderate or severe stages. PDR is the advanced stage whereby signals are sent by the retina to the body for the lack of blood supply and this triggered the growth of new blood vessels. These blood vessels can grow along the retina and the surface of the jelly-like substance (vitreous gel) which fills the centre of the eye. Although they are fragile and abnormal, they do not cause symptoms or vision loss. It is only when their thin and weak walls leak blood, severe visual loss or even irreversible blindness would occur[19].

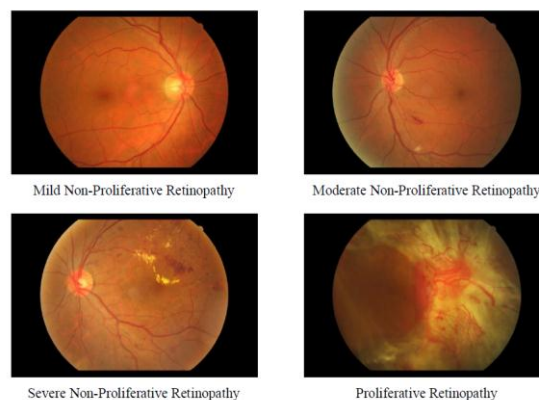


Fig. 3 Retinal images to show the different stages of diabetic retinopathy

2. STEPS INVOLVED IN PREPROCESSING AND CANDIDATE EXTRACTION

2.1 Preprocessing methods

1. WALTER KLEIN CONTRAST ENHANCEMENT

This preprocessing algorithm is proposed in [17]. This preprocessing method aims to enhance the

contrast of fundus images by applying a gray level transformation using the operator.(f')

- (1) Assigning the walter preprocessing operation into the variable [wali].
- (2) Computing the mean of the intensity values of original image (i) and assigning into the variable (mu).
- (3) Assign constant(r)=2
- (4) to (7) Finding the smallest and the largest elements in the array and assigning it into the minimum and maximum intensity levels of the original and enhanced image. Where,

f min - minimum intensity level of the original image.

fmax - maximum intensity level of the original image.

f_min – minimum intensity level of the enhanced image.

f_max – maximum intensity level of the enhanced image.

- (8) Returns a n-dimensional array with the same elements as the original image(i) but reshaped to size(i).

- (9) to (18) Implementing the formula given in base paper.

μ is the mean value of the original grayscale image.

$$f=ii(f)$$

$f'=f_im(f)$ is the enhanced image.

(20)

Performing the reshape operation for the f_im and assign it into the variable (wali). (21) to (22) Finally displayed the walter Klein contrast enhanced image.

2.CLAHE (CONTRAST LIMITED ADAPTIVE HISTOGRAM EQUALISATION):

- (1) Assign the CLAHE operation into the variable [hhi].
- (2) Performing the adaptive histogram equalization to the original image.(used to enhance the contrast of the image)
- (3) to (4) Displaying the CLAHE image.

2.VESSEL REMOVAL METHOD:

Based on the idea proposed in [18], Detect MA appearing near vessel and enhance it.

- (1) Assign the vessel removal operation into the variable [B].
- (2) Performing the inpainting algorithm for conversion of image to double precision type.
- (3) to (4)

Displaying the vessel removed image.

3. ILLUMINATION EQUALISATION:

- (1) Assign the illum equalis operation into the variable (f)
- (3) Assigning the desired intensity value.

- (4) Converting the elements of original img(i) into uint8 and then compute the mean of the intensity values and then assign into the variable [inn]

inn – local avg intensity.

- (5) Subtract the local int. value from the desired int. value.

- (6) New pixel intensity value(by using the formula)

- (7) to (8) Displaying the ill.equzld image.

5.NO PREPROCESSING:

- (1) Assign the no preprocessing operation into the variable i.

- (2) to (4) Display the no preprocess img.

2.2 Candidate extractors

1) Walter et al.

The approach proposed in [14] is a mathematical morphology based one, which recommends contrast enhancement and shade correction as preprocessing steps. Candidate extraction is then accomplished by grayscale diameter closing. This method aims to find all sufficiently small dark patterns on the green channel. Finally, a double threshold is applied. medfilt2 performs median filtering of the matrix in 2-D.

Shade corrected image=medfilt image – original image.

Creating disk shaped structuring element operation. Where R- radius(R=7)

Performing morphological closing operation on the shaded image with the strel.

The morphological close operation is a dilation followed by erosion, using the same structuring element for both operations.

Infill fills the holes in the shade corrected image.

Subtracting holes filled image by the morphological closed image and assign into the variable (vess)

Computes a global threshold (level) and assign into the variable alp.

thres=max() returns an array (thres) the same size as the variables (alp) and (inn) with the largest elements taken from alp or inn.

Product the subtracted image and the thres. And assign into the varbl fves.

Displaying the output fig.

2) Fleming et al

From the input fundus image, the vascular map is extracted by applying 12 morphological top-hat transformations with 12 rotated linear structuring elements (with a radial resolution 15 °).

Creating a line shaped structuring element with the distance(LEN =9)

Creating an empty array with the cell function.

Performing morphological opening for the shade corrected image with the strel.

Assign this output image into the variable (ope)

Note down the 1st pixel from the all 12 rotated linear elements and then find the max value out of 12 pixels.

Likewise repeat it for the entire pixels in the 12 elements. And write all the max.value in the array format and assign into the variable (vas).

Then the vascular map is subtracted from the shade corrected image and then assign into the variable (ima_les).

Apply Gaussian filter.

Perform imfilter operation (Filters the multi-D array (ima_les) with the multi-D filter (h)) and then assign in to the varbl (im_mat)

Boundaries command traces the exterior boundaries of objects, as well as boundaries of holes inside these objects, in the binary image

Display the o/p figure, for details see [2].

3) CIRCULAR HOUGH TRANSFORMATION:

Based on the idea presented in [7], we established an approach based on the detection of small circular spots in the image. The obvious choice for this procedure is to use circular Hough transformation.. Assigning the radius values in some range.

imfindcircles command is used to detect the small circular spots within radius range already specified.

Candidates are obtained by detecting circles on the images using circular Hough transformation..

Find all the bright and dark circles in the image within the radius range and then draw blue lines at bright or dark circle edges.

4) Zhang et al:

In order to extract candidates, this method constructs a maximal correlation response image for the input retinal image[16].

Applying Gaussian filter (five Gaussian masks with different standard deviations for each pixel).

Perform convolution operation for the Gaussian filtered output image with the original image.

Perform the maximal correlation coefficient operation for the convolution o/p and the original image.

Find the largest element among the 5 correlated coeff. o/p.and assign into the variable [mav map]

The maximal correlation response image is threshold with a fixed threshold value to obtain the candidates

i.e. converting the image into binary image.

Display the output image i.e., in double precision format.

Vessel detection and region growing is applied to reduce the number of candidates, and to determine their precise size, respectively.

5) Lazar et al:

Apply Gaussian filter and assign into the varbl g (Gaussian filtered o/p)

Perform the complement oprtn for the original image(which is converted to double precision format)

Perform convolution operation for the Gaussian filtered o/p and complement of the orgnl img.

Returns a label matrix (bb), containing labels for the connctd components.

Apply average filter and assign into the variable h.

Perform the convolution oprtn for the label matrix and the avg. filtered o/p.

Display the o/p figure. For more details ,see [16].

2.3 ENSEMBLE CREATION :

In this section, we describe our ensemble creation approach. In our framework, an ensemble E is a set of (preprocessing method, candidate extractor) or shortly (PP, CE) pairs. The meaning of a (preprocessing method, candidate extractor) pair is that first we apply the preprocessing method to the input image and then we apply the candidate extractor to this result. That is, such a pair will extract a set of candidates HE from the original image. If an ensemble E contains more (preprocessing method, candidate extractor) pairs, their outputs are fused in the following way:

Take 10 training images (already disease affected images). Then we present the selected preprocessing methods, which we consider to be applied before executing MA candidate extraction. There may be around 5 methods present in Preprocessing. Candidate extraction is present next to preprocessing. Similar to preprocessing there are 5 techniques or methods present in Candidate extractors.

For a single image, 25 combinations of results are available. Since there are 5 methods available in both preprocessing and candidate extraction, for each method in preprocessing 5 candidate extraction methods are processed. Likewise it repeated for 5 methods in preprocessing. So there are 25 methods proceeded for a single image. Then we should calculate the entropy for all 25 results. Then after calculating the entropy for the 25 methods, we can predict the best technique, considering whose entropy is highest. For ex., If 3rd method's entropy is highest means we determine that 3rd one is the best technique.

Likewise, we should calculate for a set of 10 training images. By following the procedure mentioned above we can determine best techniques for 10 images.

For ex. the best techniques of 10 images are like this format mentioned below:

[3 2 4 3 6 3 8 3 4 3]

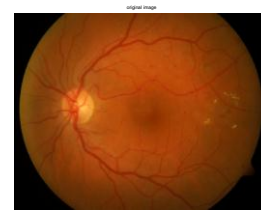
After analyzing the best techniques whose entropies are highest for 10 images, mentioned above, we can see that 3rd technique is repeated many times than other. So we can conclude that the 3rd technique is the best one[1],[6],[7],[13].

3. IMPLEMENTATION

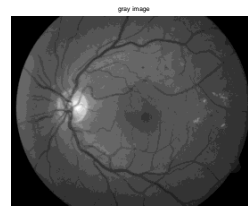
Matlab is a program that was originally designed to simplify the implementation of numerical linear algebra routines. It has since grown into something much bigger, and it is used to implement numerical algorithms for a wide range of applications. The basic language used is very similar to standard linear algebra notation, but there are a few extensions that will likely cause you some problems at first.

3.1 Screenshots

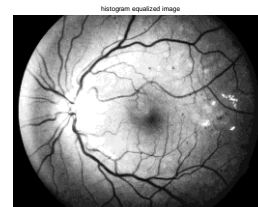
1. Original image



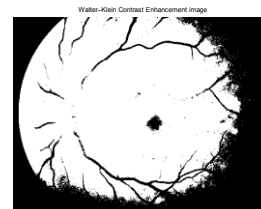2. Grayscale image



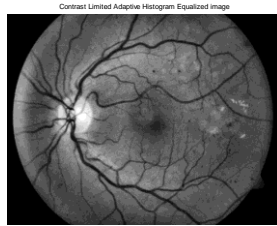
3. Histogram Equalization Image



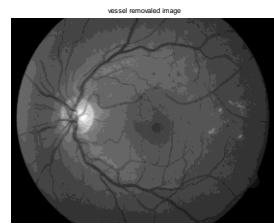
4. Walter-Klein Contrast Enhancement



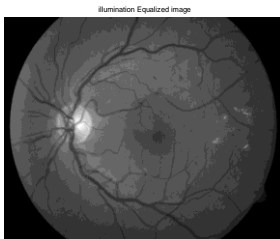
5. Contrast Limited Adaptive Histogram Equalization



6. Vessel Removal and Extrapolation



7. Illumination Equalization



CONCLUSION

We have proposed an ensemble-based MA detector that has proved its high efficiency in grading the diabetic retinopathy compared with the present techniques.

Our novel framework relies on a set of (preprocessing method, candidate extractor) pairs, from which a search algorithm selects an optimal combination.

Since our approach is modular, we can expect further improvements by adding more preprocessing methods and candidate extractors.

However, a proper screening system should contain other components, which is expected to increase the performance of this approach, as well

REFERENCES

[1] M. Abramoff, M. Niemeijer, M. Suttorp-Schulten, M. A. Viergever, S. R. Russel, and B. van Ginneken, "Evaluation of a system for automatic detection of diabetic retinopathy from color fundus photographs in a large population of patients with diabetes," *Diabetes Care*, vol. 31, pp. 193–198, 2008.

[2] A. D. Fleming, K. A. Goatman, S. Philip, G. J. Prescott, P. F. Sharp, and J. A. Olson, "Automated grading for diabetic retinopathy: A large-scale audit using arbitration by clinical experts," *Br. J. Ophthalmol.*, vol. 94, no. 12, pp. 1606–1610, 2010.

[3] H. J. Jelinek, M. J. Cree, D. Worsley, A. Luckie, and P. Nixon, "An automated microaneurysm detector as a tool for identification of diabetic retinopathy in rural optometric practice," *Clin. Exp. Optom.*, vol. 89, no. 5, pp. 299–305, 2006.

[4] M. Abramoff, J. Reinhardt, S. Russell, J. Folk, V. Mahajan, M. Niemeijer, and G. Quelled, "Automated early detection of diabetic retinopathy," *Ophthalmology*, vol. 117, no. 6, pp. 1147–1154, 2010.

[5] M. Niemeijer, M. Loog, M. D. Abramoff, M. A. Viergever, M. Prokop, and B. van Ginneken, "On combining computer-aided detection systems," *IEEE Trans. Med. Imag.*, vol. 30, no. 2, pp. 215–223, Feb. 2011.

[6] B. Antal, I. Lazar, A. Hajdu, Z. Torok, A. Csutak, and T. Peto, "A multilevel ensemble-based system for detecting microaneurysms in fundus images," in *Proc. 4th IEEE Int. Workshop Soft Comput. Appl.*, 2010, pp. 137–142.

[7] B. Antal and A. Hajdu, "Improving microaneurysm detection using an optimally selected subset of candidate extractors and preprocessing methods," *Pattern Recog.*, vol. 45, no. 1, pp. 264–270, 2012.

[8] A. A. A. Youssif, A. Z. Ghalwash, and A. S. Ghoneim, "Comparative study of contrast enhancement and illumination equalization methods for retinal vasculature segmentation," in *Proc. Cairo Int. Biomed. Eng. Conf.*, 2006, pp. 21–24.

[9] T. Walter and J. Klein, "Automatic detection of microaneurysm in color fundus images of the human retina by means of the bounding box closing," *Lecture Notes in Computer Science*, vol. 2526. Berlin, Germany: Springer-Verlag, 2002, pp. 210–220.

[10] K. Zuiderveld, "Contrast limited adaptive histogram equalization," *Graphics Gems*, vol. 4, pp. 474–485, 1994. [11] S. Ravishankar, A. Jain, and A. Mittal, "Automated feature extraction for early detection of diabetic retinopathy in fundus images," in *Proc. IEEE Conf. Comput. Vision Pattern Recog.*, 2009, pp. 210–217.

- [12] A. Criminisi, P. Perez, and K. Toyama, "Object removal by exemplarbased inpainting," in Proc. IEEE Conf. Comput. Vision Pattern Recog., vol. 2, 2003, pp. II-721–II-728. *in macular profiles*". Experimental eye Research [2006, 82(5):798-806] Journal Article DOI: 10.1016/j.exer.2005.10.002
- [13] M. Niemeijer, B. van Ginneken, M. Cree, A. Mizutani, G. Quellec, C. Sanchez, B. Zhang, R. Hornero, M. Lamard, C. Muramatsu, X. Wu, G. Cazuguel, J. You, A. Mayo, Q. Li, Y. Hatanaka, B. Cochener, C. Roux, F. Karray, M. Garcia, H. Fujita, and M. Abramoff, "Retinopathy online challenge: Automatic detection of microaneurysms in digital color fundus photographs," IEEE Trans. Med. Imag., vol. 29, no. 1, pp. 185–195, Jan. 2010.
- [14] T. Walter, P. Massin, A. Arginay, R. Ordonez, C. Jeulin, and J. C. Klein, "Automatic detection of microaneurysms in color fundus images," Med. Image Anal., vol. 11, pp. 555–566, 2007.
- [15] T. Spencer, J. A. Olson, K. C. McHardy, P. F. Sharp, and J. V. Forrester, "An image-processing strategy for the segmentation and quantification of microaneurysms in fluorescein angiograms of the ocular fundus," Comput. Biomed. Res., vol. 29, pp. 284–302, 1996.
- [16] Istvan Lazar, Andras Hajdu, and Rashid Jalal Quareshi, "Retinal microaneurysm detection based on intensity profile analysis," 8th International Conference on Applied Informatics, 2010.
- [17] T. Walter and J. Klein, "Automatic detection of microaneurysms in color fundus images of the human retina by means of the bounding box closing," Lecture Notes in Computer Science, vol. 2526, pp. 210–220, 2002.
- [18] Saiprasad Ravishankar, Arpit Jain, and Anurag Mittal, "Automated feature extraction for early detection of diabetic retinopathy in fundus images," in CVPR. 2009, pp. 210–217, IEEE.
- [19] S. Abdelazeem, "Microaneurysm detection using vessels removal and circular hough transform," Proceedings of the Nineteenth National Radio Science Conference, pp. 421 – 426, 2002.
- [20] Patel JI, Tombran-Tink J, Hykin PG, Gregor ZJ, Cree IA Institute of Ophthalmology, London, UK. "Vitreous and aqueous concentrations of proangiogenic, antiangiogenic factors and other cytokines in diabetic retinopathy patients with macular edema: Implications for structural differences