

# Mammogram Image Enhancement Techniques for Detecting Breast Cancer: A Critical Review

[ Vishwanatha, M. C Hanumantharaju, M. T Gopalakrishna, M. Ravishankar ]

**Abstract**—Breast cancer is the leading cause of deaths among female cancer patients. Breast cancer can be diagnosed in several ways such as imaging or mammography, clinical breast exam, breast self examination and surgery. In breast cancer diagnosis, the radiologist mainly uses their eyes to discern cancer when they screen the mammograms. Mammography is the most effective technique for breast cancer screening and detection of abnormalities. Calcification and masses are most common abnormality found in breast cancer. The aim of this paper is to conduct a comprehensive review of mammogram image enhancement methods to early detection of breast cancer.

**Keywords**—Mammogram enhancement, Image calcification, detection, Breast mass detection, Dyadic wavelet transform, image enhancement and denoising, Microcalcification detection.

## I. Introduction

Globally, breast cancer is ranked first among the leading cause of cancer effecting females. Mammogram is the most effective technique for breast cancer screening and early detection of masses or abnormalities. Depending on its shape, a mass screened on a mammogram can be either benign or malignant. Usually benign tumors have round or oval shapes, while malignant tumors have partially rounded shape with a spiked or irregular outline. Noncancerous or benign tumors include cysts, fibro adenomas, and breast hematomas. A cancerous or malignant tumor in breast is a mass of breast tissue that grows in an abnormal and uncontrolled way [1].

The malignant mass will appear whiter than any tissue surrounding it. Calcifications, the second abnormality that can be seen on mammogram images, are most of the time not malignant and not a sign of cancer. Successful diagnosis in mammography is dependent on detecting cancer in its earliest and most treatable stage. The challenge is to employ computer aided detection techniques for the purpose of assisting radiologist in the early detection of cancer, by processing and analyzing mammogram images [2], [3].

Although curable, especially when detected at early stages, breast cancer is a major cause of death in women. An important factor in breast cancer is that it tends to occur earlier in life than other types of cancer and other major diseases. Although the cause of breast cancer has not yet been fully understood, early detection and removal of the primary tumor are essential and effective methods to reduce mortality, because at such a point of time, only a few of the cells that departed from the primary tumor would have succeeded in forming secondary tumors. If breast cancer can be detected by some means at an early stage, while it is clinically localized, the survival rate can be dramatically increased. However, such early breast cancer is generally not amenable to detection by physical examination and breast self-examination [13]. The primary role of imaging technique is thus the detection of primary lesions in the breast [14]. Currently, the most effective method for the detection of early breast cancer is X-ray mammography. However, reading the mammograms is a difficult task that requires special training and experience for radiologists.

Emerging technological advancements have helped in the identification of breast cancer at early stages, one of the techniques being mammography. Mammography saves lives by allowing breast cancers (tumor cells) to be caught and treated while they are small (initial stage of breast cancer). Studies consistently show that more regular use of this one technology alone would reduce deaths from breast cancer by one – third [13]. However, the current practice in identifying the presence of tumors in breast tissues has a limitation of 10 percent false negative and a 20 percent false positive cases being reported [14]. This can be eliminated by developing efficient algorithms; that can more accurately identify, report and position the tumor present in breast tissues. Eventually, it saves more women from dying out of breast cancer.

Conventional enhancement techniques are mostly used to enhance masses in mammogram images; as an example, Bovis and Singh [4] and Antonie et al. [5] used histogram equalization to enhance the mammogram images. However, Schiabel et al. [6] used the histogram equalization accompanied with other techniques and as a part of a pre-processing step for mammograms enhancement. Whereas, Pisano et al. [7] used the contrast limited adaptive histogram equalization (CLAHE) in order to determine whether such a method can improve the detection of stimulated speculations in dense mammograms.

Herminger et al. [ 8 ] compared contrast limited adaptive histogram equalization (CLAHE) and histogram-based

---

Vishwanatha M. C Hanumantharaju,, M. T Gopalakrishna,  
M. Ravishankar  
Dayanandasagar College of Engineering Bangalore  
India

intensity windowing (HIW) in order to determine which of them outperforms the other in the detection of stimulated masses in dense mammograms. The goal of this paper is to provide a review of recent mammogram enhancement methods. The rest of this paper is organized as follows: section II presents details of mammogram image enhancement methods, in section III presents the conclusion.

## II. Mammogram Image Enhancement Techniques

### A. *Image Contrast Enhancement in Wavelet Domain*

Jinsang et al. [9] proposed a direct image contrast enhancement algorithm in wavelet domain. The advantage of wavelet transform/multiscale enhancement method lie in that mammogram contain features with varying scale characteristics, subtle features such as masses are mostly contained in coarse scale. Thus the different features can be selected to be enhanced within different scale. In order to develop this algorithm author used the multiscale representation of the image and an appropriate wavelet synthesis filter, then the K level wavelet transform of image. Then wavelet transform is reconstructed by his algorithm. Author also used multiscale local contrast measures in wavelet domain to local contrast enhancement. In this algorithm author used different directional contrast enhancement such as vertical, horizontal and diagonal direction contrast enhancement. In order to measure the enhancement effectiveness quantitatively, a performance measure is used that is based on Laplacian operator in region of image. This region contrast measure is characterised by superior robustness to noise and jitter in comparison with other standard contrast measures.

In this method direct image enhancement algorithm is proposed for screening mammograms. The algorithm is based on a multiscale contrast measure defined in the wavelet domain. The advantage of this are the detail in the different scale are enhanced. Figures below 1, 2,3 shows the result of this method.

### B. *Breast Sonogram and Mammogram Enhancement Using*

Sadeer et al. [10] proposed a hybrid and repetitive smoothing sharpening technique, that employs a number of sequential and also parallel steps. In order to reduce the noise author applied discrete Laplace highpass operator filter, there by image contrast is enhanced. Before applying previous stage output as input to next stage a standard deviation is calculated. After calculating standard deviation output is applied to input as two individual parallel modules. In module B iterative smoothing is applied to the input image data. The number of iteration is determined by implementing a present thresholding level of iteration decision factor. The image is

smoothed by taking the nine pixel blocks, eight neighboring pixel, then output is stored in a array. The output data array is then used to calculate a new standard deviation value. Then comparison made between new standard deviation and product of older standard deviation value and iteration decision factor. The main purpose of this iterative smoothing is to eliminate as much as possible noise from the signal. Depending on number of pixel included in image and different contrast of image requires number of iteration. The value here is subjectively determined according to the output image quality. In the next step edge array histogram is equalized. Then canny edge detection filter is applied to the filtered to accentuate contour of the possible region of interest that could have been messed by the edge detection in parallel pathway.

Whereas module G applies mean blurring filter to eliminate noise while preserving most of the details. Next the edge attribute in the image data is determined by application of maximum difference of pixel intensity. The three output are then super imposed as three bands of RGB domain by assigning the Red band to the post Laplacian image, the Green band to the filtered and normal edge detection, and the blue band to canny edge detection contours from sequentially blurred and normalized image. The 24 bit image is then converted into 8 bit gray scale array using Pal model to readily enable comparison with the original gray scale image. The result of proposed method shown figure 4, 5.

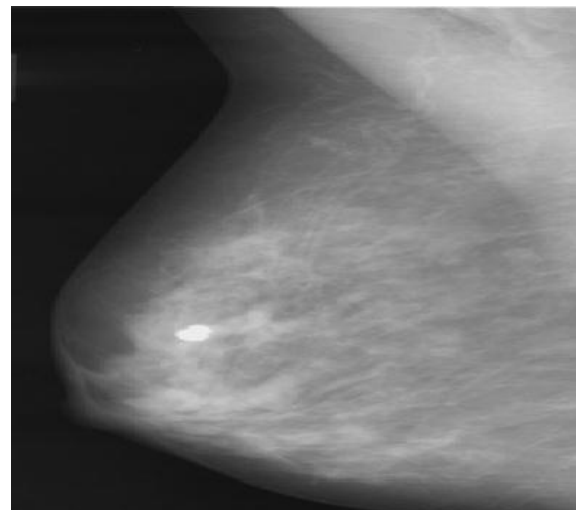


Fig. 1. Original Mammogram Image of Ref. [9]

### C. *Mammographic Image Enhancement and denoising for Breast Cancer Detection Using Dyadic Wavelet Processing*

Arianna et al. [11] proposed mammographic image enhancement and denoising for breast cancer detection

using dyadic wavelet processing. To achieve edge preserving author used gradient and laplacian filters. Gradient is more suitable when using denoising operation because gradient coefficient exhibit higher signal to noise ratios with respect to replace ones. This operator is monotonically nondecreasing function to avoid the introduction of artefacts in the mammograms. In microcalcification detection section author described a general method to accomplish multiscale contrast

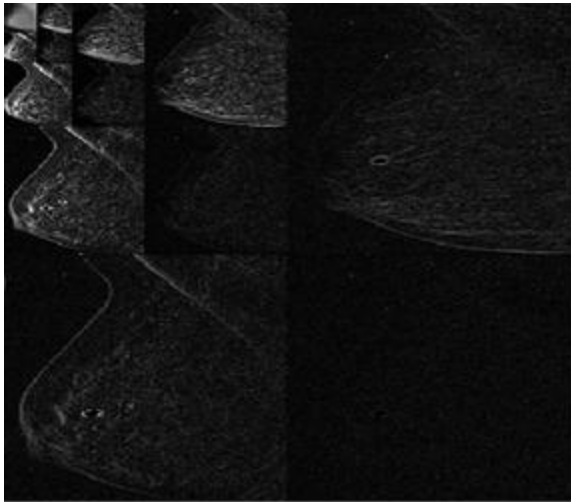


Fig. 2. 4-level subband decomposition using wavelet transform of mammogram image of Ref. [9]




Fig. 3. Region cropped from original image and regions cropped from enhanced version of original image. (a) Region cropped from original image (b) Region cropped from the enhanced image with  $\lambda=1.8$  (c) Region cropped from enhanced image with  $\lambda=2.8$  (d) Region cropped from the enhanced image with  $\lambda=4.6$  of Ref. [9]

enhancement. In the wavelet framework, linear and nonlinear enhancement operator have been proposed. To avoid the saturation of high value coefficient, which causes loss of detail

after the reconstruction process, the use of nonlinear filters used. Unfortunately designing a nonlinear enhancement function is a nontrivial task, and one has to take into account the following constraints. The nonlinear function has to be monotonically increases so that no artefacts are introduced during the processing and the reconstruction. Moreover, an area of low contrast has to be enhanced more than an area of high contrast so that saturation effect can be minimized after the rescaling procedure. Finally a sharp edge should not be blurred. Mass enhancement introduces much more difficult problem with respect to microcalcification. To operate a selective enhancement of relevant features, a segmentation method is used. To achieve multiscale edge detection, canny edge detection operator is applied. However, the dyadic scale are not sufficient for the detection of masses in mammograms, a background removal algorithm based on the properties of morphological filter such as erosion and dilation are used. The result of this method shown in figure 6.

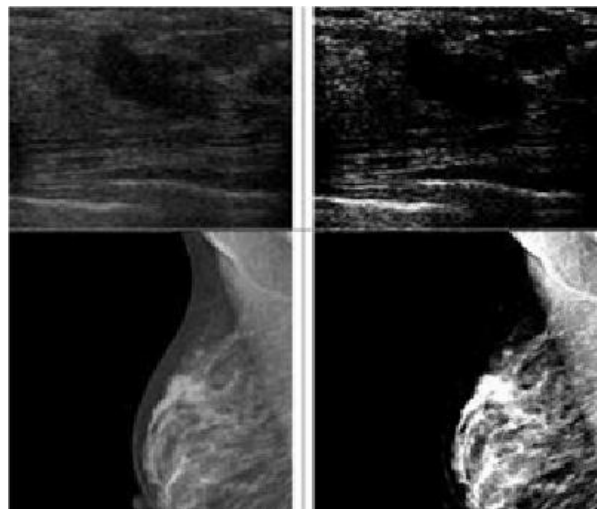


Fig. 4. Results examples of applying the Laplacian high pass filter of ref. [10]

#### D. Particle Swarm Optimization Based Contrast Limited Enhancement for Mammogram Images

Shelda Mohan et al. [12] proposed a PSO based Contrast Limited enhancement method. In the first step mean and standard deviation is calculated and initialize the enhancement parameter range. In this method it will highlight the finer detail of mammogram images. Enhanced image then given as input to the CLAHE. Here original image and enhanced parameter is given to the LCM. In the LCM, it will modify the image to produce finer detail hidden in mammogram image. In the CLAHE method divides the image in to appropriate region and applies histogram equalization to them. This method modifies the intensity value of the image employing a nonlinear methodology in order to maximize the contrast for all pixels of image. the clipping level selection of histogram

reduces the undesired noise amplification. The clipped pixels are undistributed to each gray level. The new histogram is different from the normal histogram because intensity of each pixel is limited by user selectable maximum. The CLAHE method can limit the noise enhancement. The enhancement parameter used in the LCMCLAHE algorithm is optimized using the PSO algorithm. The result obtained from this algorithm is as shown in Figure 7.

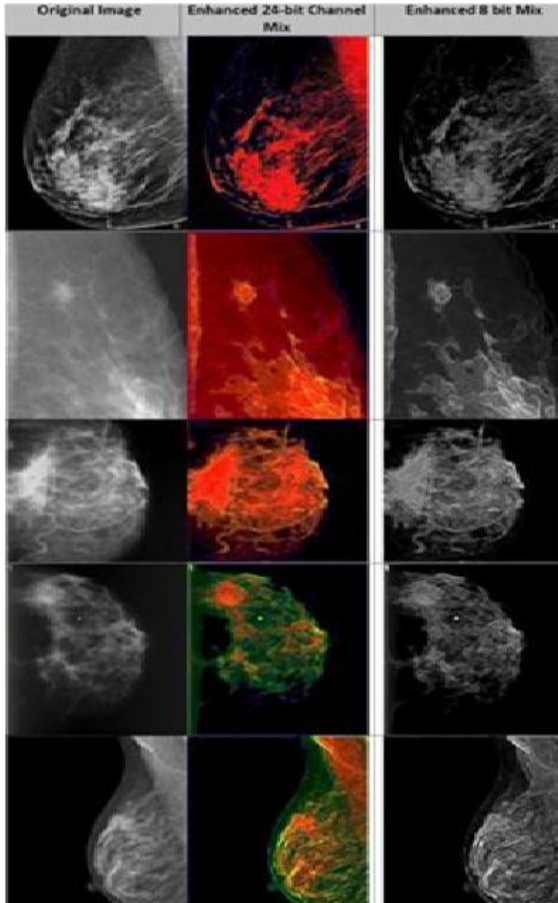


Fig. 5. Resulting mammogram image of ref. [10]

### E. Enhanced Accuracy of Breast Cancer Detection in Digital Mammograms Using Wavelet Analysis

Sharanya padmanabhan et al. [15], Proposed This method, in this method, the work is divided into three stages. The first stage covers the mammogram preprocessing and detection of the breast region. The second stage uses the output of the first stage to detect suspicious densities (abnormalities) in the breast region. This stage covers feature extraction and selection. The set of features obtained from second stage is used as an input for the next stage. The third stage is the classification stage, where a mammogram is checked for the presence of tumor based on the feature vectors obtained from

the previous stage. Any suspicious density is classified further as one having a benign or malignant tumor. This stage helps in the diagnosis of breast cancer.

In stage one it involves the preprocessing of mammogram image is segmented in to limit the search for abnormalities from the background of mammogram in order to improve the quality of the image and reduce noise. This stage consists of 3 main steps such as removal of black background, removal of label, removal of pectoral muscle.

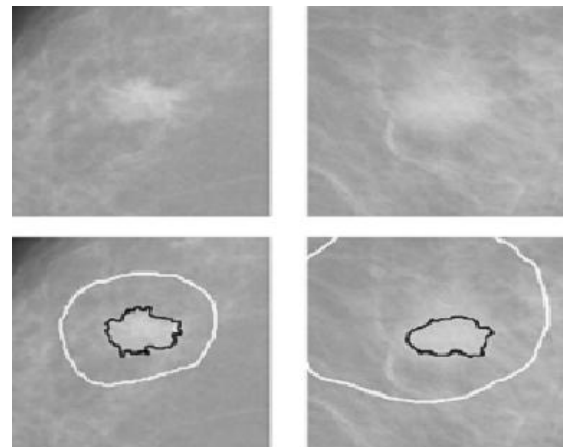


Fig. 6. Comparison between the mass identified by radiologist (white line) and that detected by the algorithm (black line). Enhancement method proposed in ref. [11]

### F. Use of normal tissue context in computer-aided detection of masses in mammograms

Rianne et al. [16] proposed a method to detect the masses in mammograms. In this CAD system consists of a preprocessing stage, an initial detection stage and an interpretation stage in which the number of false positive detected regions is reduced. Preprocessing is done in three steps: segmentation into three areas (breast region, background, and pectoral muscle), pectoral equalization, and peripheral enhancement. Candidate mass regions are detected by performing an initial Detection. In this stage, five features are computed for each location on a regular grid in the image. These features are two gradient concentration measures, two spiculation measures, and one measure indicating the scale at which most spiculation is present. The features are fed into an ensemble of five neural networks that are each randomly initialized and trained on a small data set. For each location at the grid a likelihood score is computed by averaging the five network outputs. Together, these likelihood scores form a likelihood image. This likelihood image is smoothed and each local maximum in the likelihood image that exceeds a threshold is selected as a

candidate mass location. For each local maximum in the likelihood image a candidate mass region is segmented using a segmentation method based on dynamic programming. In the interpretation stage, the candidate masses are classified into normal or malignant tissue by computing a set of features for each segmented region. These features are the input for a second neural network classifier. By applying a threshold on the output of this classifier, the number of false positive detections is reduced without a large reduction in sensitivity. The features used in this stage measure region contrast, location, linear texture, density, region size, and compactness. In addition to these features, the five gradient concentration and spiculation features and the mass likelihood score computed in the initial detection stage are also used by the second stage classifier. Context features can be computed based on likelihood scores in several image areas. Context measure for immediate surrounding of the candidate mass region, context measure for the whole breast, context measure for a specific band.

When computing the three context features, the likelihood scores assigned to locations inside the candidate region and to locations very close to the segmentation border (2.4 mm and closer) were not used. In general, small likelihood scores are assigned to the majority of locations in an image while large likelihood scores are assigned to very few locations. There by computed th percentiles for the likelihood scores because this measure is less affected by the large amount of small scores than a measure such as the mean or median. The different steps involved in the method are shown in figure 11.

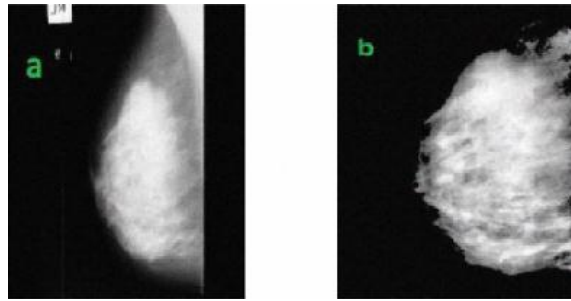


Fig. 8. Normal mammogram, (a) Input image with label; (b) Preprocessed image after pectoral muscle suppression of ref. [15]

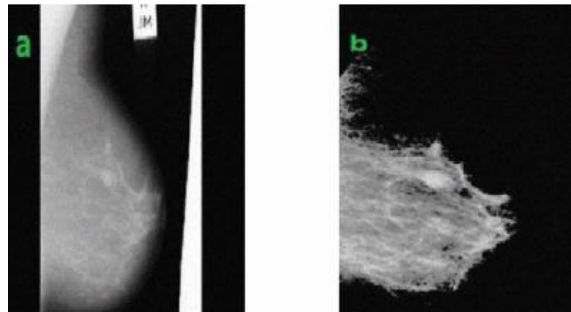


Fig. 9. Benign tumor mammogram, (a) input image with label; (b) preprocessed image after pectoral muscle suppression of ref. [15]

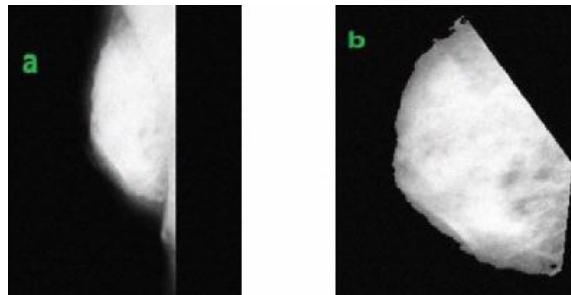


Fig. 10. Malignant tumor mammogram, (a) input image with label; (b) preprocessed image after pectoral muscle suppression of ref. [15]

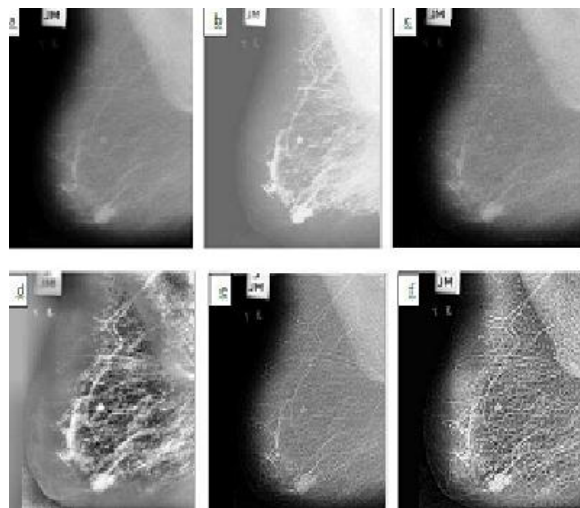


Fig. 7. Enhanced result of fatty mammogram image (a) Original image (b) Image enhancement using histogram equalization (c) Image enhancement using USM (d) Image enhancement using CLAHE (e) LCM enhanced image (f) Image enhanced by the method proposed in ref. [12].

### III. CONCLUSION

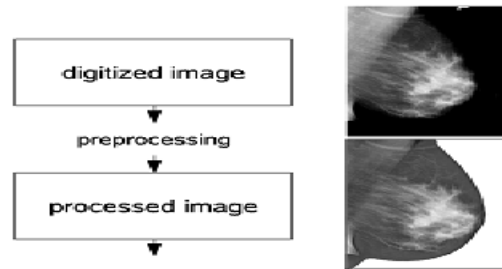
This paper presented a comprehensive review of mammogram image enhancement methods. From the review, it is obvious that the results produced from the different enhancement techniques are best suited for enhancing both masses and micro-calcifications.

## References

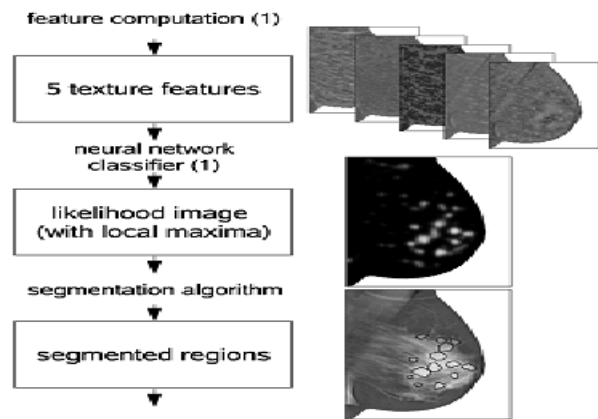
- [1] Blackwell M., Nikou C., DiGioia, A.M., Kanade, T., "An Image Overlay system for medical data visualization," Med. Image Analysis. 4, pp 67- 72, 2000.
- [2] Altrichter M., Ludanyi, Z., Horvath, G., "Joint analysis of multiple mammographic views in cad systems for breast cancer detection," In: Proc. of Image Analysis. 14th Scandinavian Conference, 2005.
- [3] Sajda P., Spence C., Parra L., "A multi-scale probabilistic network model for detection, synthesis and compression in mammographic image analysis," Med. Image Anal. 7, pp 187-204, 2003.
- [4] Bovis K., Singh S., "Detection of masses in mammograms using texture features", In: Proc. of the 15th Int. Conf. on Pattern Recognit. (ICPR00), pp 267-269, 2000.
- [5] Antonie M., Zaiane O.R., Coman A., "Application of Data Mining Techniques for Medical Image Classification," In: Proc. of Second Intl. Workshop on Multimed. Data Min. 2001.
- [6] Schiabel H., Santos V. T., Angelo M.F., "Segmentation technique for detecting suspect masses in dense breast digitized images as a tool for mammography CAD schemes." In: Proc. of the 2008 ACM Symp. On Appl. Comput., 2008.
- [7] Pisano E.D., Zong S., Hemminger B.M., DeLuca M., Johnston R.E., Muller K., Braeuning M.P., Pizer S.M., "Contrast limited adaptive histogram equalization Image Processing to Improve the Detection of Stimulated Speculation in Dense Mamms," J. Digit. Imaging., pp 11, 193 200, 1998.
- [8] Hemminger B.M., Zong S., Muller K.E., Coffey C.S., DeLuca M.C., Johnston R.E., Pisano E.D., "Improving the detection of simulated masses in mammograms through two different image-processing techniques," J. Acad, pp 845-55, 2001.
- [9] Jinsang Tang, Xiaoming Liu, Qingling Sun , "A direct image contrast enhancement algorithm in the wavelet domain for screening mammograms," IEEE Trans. Signal Processing., vol. 3, 2009.
- [10] Sadeer G. Al-Kindi , Ghassan. A. Al-Kindi, Breast sonogram and mammogram enhancement using hybrid and repetitive smoothing-sharpening , IEEE Trans.Med.Imag.,vol. 16 no. 5 ,2011.
- [11] Arianna Mencattini, Marcello salmeri, Robert Lojaco, Manuela Frigero, Federica Caselli, "Mammographic images enhancement and denoising for breast cancer detection using dyadic wavelet processing," IEEE Trans. Instrumentation and Measurement, vol. 57, no. 7, 2008 .
- [12] Shelda Mohan, T. R. Ramesh , "Particle swarm optimization based contrast limited enhancement for mammogram images," Proc. INT. Conf. on ISCo. 2013.
- [13] A. Gawande, "Suggestions for Becoming a Positive Deviant, in Better: A Surgeons Notes on Performance", 2nd ed. NY: Picador, 2007, ch. 7, pp. 249-253

- [14] G.M. Brake and N. Karssemeijer, "Segmentation of suspicious densities in digital mammograms," International Journal of Medical Physics, 28, 259-266, 2001

### preprocessing stage:



### initial detection stage:



### interpretation stage:

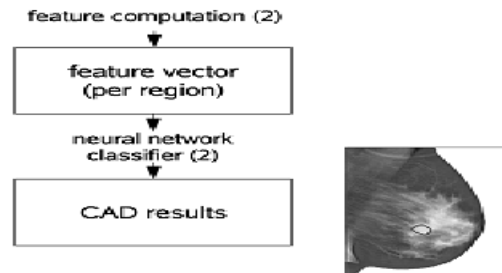


Fig. 11. Schematic overview of the CAD system consisting of three stages: a preprocessing stage, an initial detection stage, and an interpretation stage of ref. [16]

- [15] Sharanya Padmanabhan , Raji Sundararajan , "Anhanced accuracy of breast cancer detection in digital mammograms using wavelet analysis," IEEE Trans. Img. Proc. 2012.
- [16] Rianne Hupse and Nico Karssemeijer, "Use of Normal Tissue Context in Computer-Aided Detection of Masses in Mammograms," IEEE Trans.Med.Imag.,VOL. 28, NO. 12, DECEMBER 2009.