

A Review of Diagnose Hypertension Using Fundusoscopic Images with Nipping in Intersections of Arteries and Veins

A.K.A.Wijewickrama¹, K.A. Dilini T. Kulawansa²

¹Faculty of Information Technology, University of Moratuwa, Sri Lanka

²Department of Computational Mathematics, University of Moratuwa, Sri Lanka

Abstract - In modern medical field detecting nipping is done manually by ophthalmologists to detect hypertension of a patient. This is mainly done by the doctor using a gonioscope or by examines a fundus image of the patient. This proceeding may takes extensive amount of time and when the ophthalmologist has large number of patients to examine, this can be frustrating. In this review I discuss how this process can be automated under the supervision of an expert so that when the ophthalmologist receives the fundus image of a patient, he will get data of that patient that if he has hypertension symptoms in his fundus or not. With an assisting tool like this the efficiency of a typical fundus examine process can be increased in an exponential rate. A system like this will also open more and more ways to other approaches regarding same methods and technologies.

Keywords: Technology, Hypertension, Fundus, Nipping, Arteriovenous, Retinopathy, AV, Cotton-wool spot

I. INTRODUCTION

Technology is rapidly growing up and being applied in various subjects. Medical field is taking a remarkable place among them. In terms of examine the eye and matters related to eye diseases, technology has done a huge service. Such as creating the gonioscope to fundus camera.

When an Ophthalmologist check the eye for abnormalities using the gonioscope, sometimes it's not clear to identify them because it takes a lot of practice and experience to identify retinal abnormalities by just using a gonioscope. So as a solution we take a photo of the fundus called as fundus image and then the doctor examines it and diagnoses the problem. The main problem is this process is very time consuming. Because even when the doctor gets the fundus image it takes some considerable amount of time to detect the abnormalities and come to a conclusion.

Arteriovenous nipping (a bump in intersections of arteries and veins in the retina) is one of the main abnormalities related to hypertension. But sometimes

it's not much visible to the naked eye in a fundus image. But with this application we can tell the doctor before he examines the fundus image that if this patient has abnormalities regarding hypertension or not. With this data it'll be easy for the doctor to diagnose abnormalities and it most certainly will speed up the process.

II. OVERVIEW

Hypertension accelerates plaques in retinal vessels. These plaques are made up of fat, cholesterol, calcium and other substances found in blood. With this, the blood pressure of veins increases than the usual and this will cause hypertensive retinopathy. The earliest and least harmless abnormality in the fundus we can see caused by hypertension is nipping (technical term for bump) in intersections of arteries and veins in the fundus. As in figure 1 below, we can see that the artery appears as a "bottle neck" in the intersection of artery and vein shown by the arrow. This is how the nipping phenomenon appears in a fundus image.

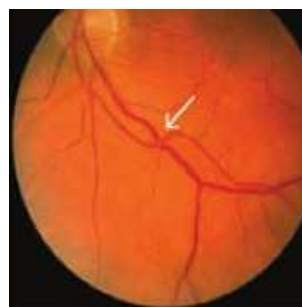

Figure 1. Nipping in artery and vein intersection in the fundus

But after sometime if the hypertension level increases and becomes severe, it will cause blood vessels to leak and this will cause hard exudates or macular edema. This will become visible as white spots and these white spots are also called as cotton-wool spots because of how they appear. In figure 2 below we can see that there are a lot of white spots in the middle

of the eye (that's where the macular is located). This level is more severe than in figure 1 and need immediate medical attention.

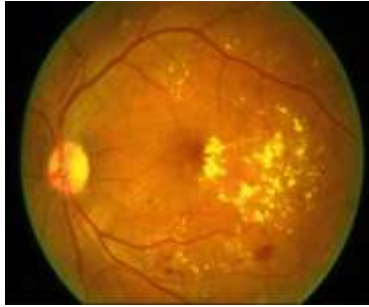


Figure 2. macular edema

If proper treatments are not supplied, this level will increase more and becomes more severe and becomes Papilledema or flame haemorrhages. If this happens urgent treatment is required [7]. The patient will suffer complete blindness without recovery if proper treatments are not supplied. Basic treatments for this differ from weight loss to surgical procedures (laser treatments). As in figure 3 below we can see that red blood areas are all over the retina and macular area. And also we can't clearly see arteries. This is due to blood leakage in the eye. This level needs immediate medical attention. Otherwise this will lead to complete blindness without recovery.

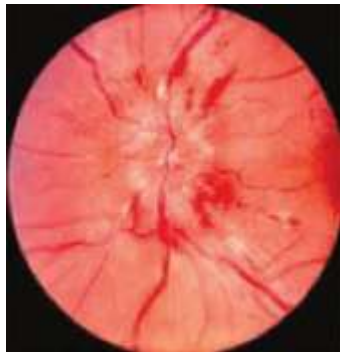


Figure 3. Papilledema

All these problems can be prevented if we can detect nipping from fundus and diagnose hypertensive abnormalities in the fundus. Because early treatments are always easy and always better. That's the main importance of detecting nipping in intersections of arteries and veins in the fundus and diagnosing hypertension through that.

III. MAJOR RESEARCHES IN NIPPING IN FUNDUS

Hypertension (high blood pressure) is now a worldwide issue that has an impact over 25%

populations in Sri Lanka and approximately one billion worldwide [3]. This also is one of the most important risks for stroke. Even milder degree of hypertension elevation can boost the chance of cardiovascular events (and event that can cause damage to the heart muscle). High blood pressure (clinically known as hypertension) works as a silent killer for many years before organ damages are clinically apparent. Therefore, it is important to detect hypertension in an early age before damages are unrecoverable [2].

The retina can give a clear window to study human circulation. Retinal arteries and veins can be easily detected through a gonioscope or a fundus image. Poorly treated systematic high blood pressure will damage the retinal microcirculation so recognizing hypertension retinopathy can be important to prevent cardiovascular risk for hypertensive patients [4].

The severity and extent of retinopathy is representing generally on a scale of one to four. In grade two there is more severe or tighter constrictions of the retinal artery (arteriovenous or AV nipping). In grade three there are signs of grade two but also retinal edema, micro aneurysms, retinal bleeding and cotton wool spots (fluffy white lesions on the retina). In grade one the retinal artery is mildly narrowed. And grade four shows signs of optic disc swelling and macular edema (build-up of fluid in the macula) [5].

A key complication of hypertension is arteriovenous nipping. This means that arteries are thickened and push on the nearby veins and give them a nipped appearance as they cross the arteries. Figure 4 indicates How nipping appears in a fundus image. We can check the arteries in intersections of AV and see that the artery is having a bottleneck when the vein is going on top of it. This is the nipping phenomenon in the fundus.

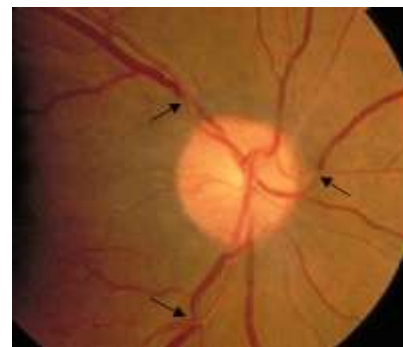


Figure 4. Image indicating nipping

In Figure 5 we can also see another fundus image that indicates nipping. Here we also can see that the artery is having a bottleneck in the intersection of AV. This is the nipping phenomenon and if this happens we

can simply say that the patient is suffering from hypertension.

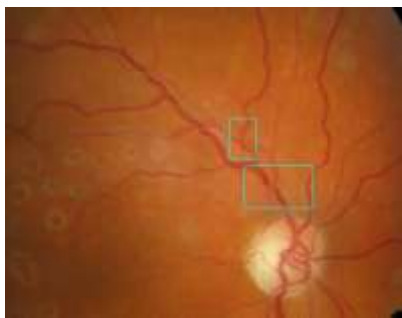


Figure 5. Image indicating nipping

By detecting this nipping (technical term for the bump in intersections of arteries and veins) we can say that if the patient is suffering from hypertension or not and can prescribe proper treatments in an early stage [6]. Figure 6 indicates an eye without nipping therefore without hypertension. We can see here that arteries very clearly in every AV intersection. There are no bottlenecks in any intersection. Also there are no blood hemorrhages or cotton wool spots. Therefore this is an eye (figure 6) that never suffered from hypertension.

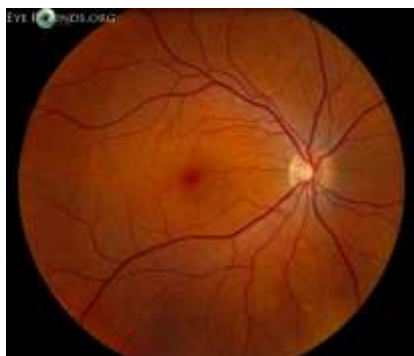

Figure 6. Image without nipping (healthy eye)

One research has observed 47 high- resolution fundus images. This dataset were obtained by 2 separate population based researches. Outputs of this study have shown a great correlation between AV nipping and hypertension with trained expert grading and the accuracy level of this output is 88-89%. With this accuracy level we can clarify that more severe and moderate artery vein nipping can be extracted more accurately [11].

Treatments for hypertension are mainly lifestyle changes and medications. A diet with high level of vegetables and fruits may help lower blood pressure and reducing salt intake, caffeine and alcohol. Smoking, being overweight is also reasons for hypertension. Therefore regular physical activities will help reducing hypertension. There are also

medications for hypertension such as beta blockers, diuretics or ACE inhibitors [8].

But if the condition is severe, it may cause irreversible eye damage that causes permanent vision problems and may cause complete blindness [1].

IV. OTHER RESEARCHS IN HYPERTENSION AND EXAMINE FUNDUS IMAGES

AV nipping (also called as AV nicking) is an abnormality caused by hypertensive retinopathy. This feature can be detected when a small artery is over a vein. Because of this intersection, the vein expands to both sides of the intersection point. Artery vein nipping phenomenon has found as an early indicator for diseases relating to eye such as hypertension, branch retinal vein occlusion and acute stroke.

A. Detecting nipping using algorithm

Nipping in artery and vein intersection can be extracted by calculating the artery-vein nipping severity by a computer based algorithm. For this we can use techniques such as image segmentation, acquisition, AV classification and measure width of vessel. The artery vein nipping values achieved by this research indicates a great correlation between nipping and hypertension with 88-89% accuracy level with expert grading. This clarifies that more severe artery vein nipping can be detected more accurately [8].

B. Detection nipping using best-buddies Similarity

To detect nipping in artery and vein intersection we can use BBS computation (best buddy similarity) to extract data from the image. First we calculate space differences for every point couple. Then we find BBP (bits per pixel) between candidate window and the template. This best buddies' similarity (BBS) was established on the following hypothesis. That hypothesis is that the aimed pixels under distinct backgrounds area may follow the same probability distribution always. And this analogy among these pixels is measured by estimating the number of identical feature points in the template and the target image applicant space [13].

c. Detecting different levels of hypertension and Calculating Arteriovenous ratio

There are four severity levels for hypertension. Level 1 is the lowest one and it will cause the retinal arteriolar patterns to narrow. Level two will cause the retinal arteries to shrink. AV nipping will happen in this stage. In level 3 we can detect cotton wool spots and retinal hemorrhages from the fundus image. In level four optic disc will begin to swell and blur. In this level there's a great risk that the patient might have strikes or cardiovascular diseases [10].

So as above mentioned, nipping will happens in stage 2 which is an early and preventable stage. With increasing the dataset for the system to be trained to detect AV nipping and diagnose hypertension, the accuracy level will also increase. So, in order to get higher accuracy level, we must get different data sets from different regions, different countries [9].

D. Hypertension vs. Obesity

There's also a strong link between obesity and hypertension. Proper treatments for early level of hypertension are regular exercise and dieting. These are the advantages we can get from early diagnosis of hypertension [12].

V. CHALLENGES

When detecting hypertension through extracting nipping in intersection of arteries and veins in fundus images, this system or the approach should have a high level of accuracy and also efficient. Because accurate diagnosing can lead to further treatments and prevention of future severe level of diseases. If not it may lead to complete blindness without recovery. So it's very important that the system should have high accuracy level. So the output of the system should always be checked by an expert before implementing. If not the patient might get false treatments and it might lead to more disasters.

VI. COMPARISON OF RELATED RESEARCHES

Table 1 contains information about related researches, review papers, journal articles and conference papers. All these are related to hypertension and detection of hypertension through

nipping in fundus and extracting features regarding nipping from fundus images.

TABLE 1: Comparison of relevant Researches

| Paper Title | Problem Addressed | Drawbacks |
|---|--|---|
| Prevalence of Reno vascular Hypertension in Patients with Grade III or IV Hypertensive Retinopathy [1]. | Why hypertension is all around the world. | Not able to get data from all around the world to come to a general conclusion. |
| Hypertensive Retinopathy: Some answers, more questions [2]. | Hypertensive Retinopathy and their implications for clinical care. | To detect hypertensive retinopathy, the process should be more efficient. |
| The prevalence, predictors and associations of hypertension in Sri Lanka: a cross-sectional population bases national survey [3]. | Study community prevalence, pattern differences of hypertension in a large sub culture of south Asian adults to understand different risk factors. | Lack of public health initiatives to motivate healthier lifestyles to prevent obesity thus avoids hypertension. |
| Clinical Methods: The History, Physical, and Laboratory Examinations [4]. | Study fundus images and through that diagnose eye related and other diseases accurately. | Need expert level experience to diagnose a disease accurately and even so it's a very time-consuming process. |
| Making Sense of Hypertensive Retinopathy[5] | The reasons for Hypertensive Retinopathy and how to control it and avoid it. | Hypertension leads to irreversible level if not treated properly. So, it should be detected in an early stage. |
| Hypertensive retinopathy signs as risk indicators of cardiovascular morbidity and mortality [6]. | Classification and diagnosing hypertension through the eye. | High level of variety in fundus with the level of hypertension the patient has at the moment. |
| A Review on the Extraction of Quantitative Retinal Micro vascular Image Feature [8]. | Quantitative retinal micro vascular feature extraction from fundus images. | The accuracy of the output is lower due to the variety of the dataset. |
| Annotated Dataset for Vessel Segmentation and Calculation of Arteriovenous | Detecting abnormalities happen in fundus due to hypertensive retinopathy. | To increase the accuracy, need a large dataset with high level of variety. |

| | | |
|---|--|---|
| Ratio [9]. | | |
| Ridge based vessel segmentation in color images of the retina [10]. | Automated segmentation of vessels with a fundus image. | Need a large dataset for more accuracy. |
| Ophthalmologic Manifestations of Hypertension [11]. | Find the correlation between hypertension and nipping in artery and vein intersections in the fundus. | Need to extract nipping features to diagnose hypertension. |
| Retinal Vessel Diameters and Obesity: A Population-Based Study in Older Persons [12]. | Find the correlation between arteries and veins diameters in retina, vessel wall signs and BMI in aged people. | Only focused in older people for the research. |
| Optic Disc Detection from Fundus Photography via Best-Buddies Similarity [13]. | How to detect the optic disc automatically with the help of fundoscopic images using BBS. | The accuracy may vary with the template using for the system. |

VII. IMPORTANCE OF AUTOMATED DETECTION OF HYPERTENTION

Detecting hypertension in an early stage can prevent complete blindness and variety of other diseases such as cardiovascular diseases and stroke. Nipping in intersection of artery and vein happens in a very early age of hypertension. Therefore, if we can detect nipping in fundus, it leads to detecting hypertension in an early step and it may lead to preventing other severe effects such as stroke, cardiovascular diseases which may cause death. Usually this is done by an eye doctor manually and it takes a considerable amount of time to detect nipping and diagnose hypertension through that. But if there is a system that can automatically do that, it will decrease the gap between medical field and modern technology thus leading to many more possibilities of finding and diagnosing more diseases with efficient and accurate manner.

In modern world there are many approaches that can be done to extract features like this and technologies. Such as neural network, machine learning and augmented reality. All these approaches can be embedded with image processing techniques. With methods like this we can achieve a level of accuracy that was considered impossible. Therefore, with modern day technology and new knowledge we attain through medical field and other fields, we can prevent diseases like these all around the world.

VIII. FUTURE DIRECTIONS

There are a large number of eye related diseases in the world and most of them can be identified through a fundus image. But it's not practical for an ophthalmologist to detect them all the time with high efficient rate. But with the same approaches that have been discussed in this paper, we can improve the system to detect more abnormalities such as for Glaucoma, Central Retinal artery and vein occlusion.

With the technology changing in an exponential capacity, it's possible and practical to use more and more approaches to connect medical field with technology. Researches like this can help find correlations between more abnormalities and diseases thus diagnose diseases in a more efficient manner. With applications like this we can create the foundation to detect and diagnose diseases automatically in the future. But for that we need almost 100% accuracy. With approaches like these and developing technology we have today, we can achieve that point.

IX. CONCLUSION

As discussed in this paper detecting nipping in fundus can be very helpful for the doctor if that can be done automatically before the expert analyze the image. It also is very obvious that we can do that by image processing and machine algorithms with high accuracy level.

If this is done it can help the doctor in the long run and it will help speed up the process of the doctor analyzing the fundus image and diagnosing hypertension.

Some areas that could use as approaches are mentioned in this paper. Such as computer-based algorithms and Best buddy similarity. Also, there are mentions of researches that have indicated the correlation between hypertension and nipping, hypertension and cardiovascular diseases, hypertension and stroke.

At first getting a higher accuracy level will be very difficult but with modern day technology and approaches that have been mentioned in this paper, it's possible to achieve our goal. This can be a huge turning point in both software field and medical field because researches and applications like this will help fill in the gap between those two important fields.

Acknowledgement

First of all, my sincere thanks go out to Dr. L. Ranathunga, Department of Information Technology, Faculty Information Technology, University of Moratuwa, for giving me full support and giving me encouragement to do this research successfully and also, I'm thankful for all others including my family and friends who helped me carry out this study successfully.

References

- [1] Bruce A. Davis, M.D., James E. Crook, M.D., Ph.D., Robert E. Vestal, M.D. and John A. Oates, M.D. "Prevalence of Renovascular Hypertension in Patients with Grade III or IV Hypertensive Retinopathy".
- [2] Br.J Ophthalmol. 2005 December "Hypertensive Retinopathy: Some answers, more questions".
- [3] P. Katulanda, P. Ranasinghe, R. Jayawardena, G.R. Constantine, M.H. Rezvi Sheriff, D.R. Matthews "The prevalence, predictors and associations of hypertension in Sri Lanka: a cross-sectional population bases national survey" 2014 January 16.
- [4] Henry Schneiderman "Clinical Methods: The History, Physical, and Laboratory Examinations 3rd edition. Chapter 117. The fundoscopic Examination".
- [5] Hitra Badii, Steven Kim MD "Making Sense of Hypertensive Retinopathy" 2016 January 06.
- [6] Tien Yin Wong, Rachel McIntosh "Hypertensive retinopathy signs as risk indicators of cardiovascular morbidity and mortality" 2005 January 01
- [7] J. Murray Longmore, Murray Longmore, Ian Wilkinson, Edward Davidson, Alexander Foulkes, Ahmad Mafi "Oxford Handbook of Clinical Medicine"
- [8] Kuryati Kipli, Mohammed Enamul Hoque, Lik Thai Lim, Muhammad Hamdi Mahmood, Siti Kudnie Sahari, Rohana Sapawi, Nordiana Rajae, Annie Joseph "A Review on the Extraction of Quantitative Retinal Microvascular Image Feature"
- [9] Shahzad Akbar, Taimur Hassan, M. Usman Akram, Ubaid Ullah Yasin, Imran Basit "Annotated Dataset for Vessel Segmentation and Calculation of Arteriovenous Ratio"
- [10] J.J. Staal, M.D. Abramoff, M. Niemeijer, M.A. Viergever, B. van Ginneken, "Ridge based vessel segmentation in color images of the retina", IEEE Transactions on Medical Imaging, 2004, vol. 23, pp. 501-509.
- [11] Kean Theng Oh, MD "Ophthalmologic Manifestations of Hypertension"
- [12] Jie J. Wang , Bronwen Taylor , Tien Y. Wong , Brian Chua , Elena Rohtchina , Ronald Klein , Paul Mitchell "Retinal Vessel Diameters and Obesity: A Population-Based Study in Older Persons"
- [13] Kangning Hou, Naiwen Liu, Weikuan Jia, Yunlong He, Jian Lian, Yuanjie Zheng "Optic Disc Detection from Fundus Photography via Best-Buddies Similarity"

About Author (s):

| | |
|--|---|
|  | <p>A.K.A. Wijewickrama¹ Faculty of Information Technology University of Moratuwa Sri Lanka +94 710510274</p> |
|  | <p>K.A. Dilini T. Kulawansa² Department of Computational Mathematics Faculty of Information Technology University of Moratuwa Sri Lanka +94 777316627 / +94 714434529</p> |