

Utilization of fish fat for production of biosurfactant with multifunctional activities

Santanu Sana and Sriparna Datta*

Abstract— Fat poses disposal problem and remain unutilized in eating establishments. We aimed at utilising *Catla Catla* fish fat as a cheap source of carbon for production of biosurfactant with isolated strains of bacteria. Biosurfactant is itself an eco-friendly and biodegradable chemical with multifunctional activities. We have isolated and characterized a Rhamnolipid biosurfactant produced by *P. aeruginosa* DSM 50071. It showed enhanced excisional wound healing activity (96%) on topical application at the wound site compared to untreated control rats ($p < 0.05$). The higher tensile strength and higher %wound contraction for the treated group as compared to untreated revealed wound closure efficiency of the biosurfactant. Histopathological study also supported wound closure efficiency by promoting collagen synthesis. Thus our study serves dual purpose of combating environmental pollution - by solving the fish fat disposal problem with its effective utilization and reducing the cost of biosurfactant production which is an effective alternative to the toxic chemical surfactants used in industries.

Keywords— *Fish fat, Rhamnolipid, Tensile strength, Wound healing, Wound index*

I. Introduction

Animal fats are largely available and used for soap production and also as a cooking medium. But in recent years vegetable oil has replaced fats in food industry. Edible fats are 40% cheaper [1] and non-edible even cheaper than the vegetable oils. Disposal of the animal fats pose serious problem of clogging in the sewer lines. These fats can be safely utilized for fermentation processes with microbes for production of value added products and thereby reduce the

cost of production as well as solve the problem of fat disposal. *Catla catla* fish fat is largely available in the local markets of India and no work has yet been done on its industrial utilization.

Rhamnolipid, a *Pseudomonas aeruginosa* DSM 50071 derived biosurfactant was produced by utilizing *Catla catla* fish fat. Rhamnolipid is a glycolipid type biosurfactant comprising of hydrophilic part i.e. rhamnose and hydrophobic part of β -hydroxy fatty acid linked by β -glycosidic bond between these two [2]. Excisional wounds are most common hazard in hospital premises which are randomly treated with traditional antibiotics that lead to resistance development of the pathogenic microorganisms. Hence a newer substitute for an antibiotic is the need of today. Rhamnolipid is already known to have keratinocyte stimulating activity [3] which may promote wound healing. Wound is a degree of disruption of the skin continuity. Healing of wound is an innate, compound procedure followed by cellular events like cell proliferation, cell migration, re-epithelialization, angiogenesis, inflammatory phase and oxidative reaction [4]. Various types of insults can result in injury which lead to consequences of incised wound, lacerated wound, abrasion, contusion, ulcer and burn wound [5]. Although the various stages of wound healing are overlapped and complex biological changes between blood cells, cutaneous parenchymal cells, soluble factors and extra cellular matrix takes place, still the healing process can be divided into three sequential steps: inflammation, proliferation and migration of tissue cells [4].

The initial inflammatory phase comprises of inflammatory response by activating fibroblasts, keratinocytes and proliferative phase leads to increase in the number of fibroblasts and blood vessels at the wounded area [6]. The final step of proliferative phase is wound remodeling phase whereby the component of collagen fiber stabilizes the

Santanu Sana
Department of Chemical Technology, University of Calcutta
India

Sriparna Datta
Department of Chemical Technology, University of Calcutta
India

The work was funded by University Grant Commission, India.

tissue tensile strength over time [7]. We are pioneer to study the effect of rhamnolipid on excision wound comprising of physical studies like wound contraction rate, wound index, tissue tensile strength supported by histological studies.

II. Materials and methods

A. *Materials*

All reagents and solvents were of analytical grade and Framycetin sulfate (1% w/w) ointment was from Aventis Pharma Ltd (India). Rhamnolipid was prepared and purified in our laboratory using *Catla catla* fish fat [8].

B. *Microorganism and media component*

The microorganism was isolated from fat contaminated soil and identified as *Pseudomonas aeruginosa* DSM 50071 after 16S rRNA gene sequencing (Genebank accession no. NR 026078).

C. *Preparation, isolation and identification of biosurfactant*

The biosurfactant was prepared and isolated following the method described by Sana *et al.* [8] Identification was done by treating with Molisch's reagent, FTIR.

D. *Preparation of rhamnolipid ointment*

Cetostearyl alcohol, white soft paraffin and liquid paraffin was melted in a beaker to form the ointment base and 50 mg rhamnolipid in 5 ml distilled water was mixed thoroughly with constant stirring to prepare the ointment.

E. *Animal study design*

24 Young male Wister rats (150 g to 200 g) were acclimatized for 7 days, fed with standard pellet diet following the procedure as per OECD Guidelines approved by Institutional Animal Ethics Committee (IAEC, registration no. SVP/PG/348A/2015).

Dorsal skin of each rat was shaved 24 hrs before experiment, anaesthetized with i.p. injection of thiopentone sodium at a dose of 35 mg/kg and depilated dorsum was dressed with 70% ethyl alcohol. Two full thickness punch

wounds of 8 mm diameter were inflicted on the back side of each rat with the help of a sterile circular blade [9], Acu-Punch (Acuderm Inc., FL, USA), under anaesthetic condition. Animals were divided into groups containing 6 animals each.

Group I: Untreated (negative control) group (NC)

Group II: Normal paraffin treated group (OB)

Group III: Rhamnolipid (5 mg/ml dose) treated group (RL)

Group IV: Framycetin sulphate ointment (positive control) treated group (FS)

The entire wound was left undressed and medications were applied topically on the wound every day. Treatment was carried for 10 days for total healing of the wound.. Animals were weighed and photograph of the wound site were taken every alternate day as a measure of gross nutritional status and clinical health.

F. *Determination of wound contraction rate, wound index and tensile strength*

Percentage wound contraction and wound index (Table 1) were calculated on day 0, 5, 7 and 10 respectively following the method of Biswas *et al* [10].

The strength to detach the newly formed tissue was evaluated using a tensiometer (M/S Excel Enterprises, Kolkata, India) after the treatment and expressed in g [11].

G. *Histological study*

Regenerated granuloma tissue was collected on day 10 for histological study to perceive various steps of healing.

H. *Statistical Analysis*

Statistical analysis was done as mean \pm standard deviation using GraphPad Prism 5.01 ($P < 0.05$).

Table 1 Arbitrary scoring system for measurement of wound index

Gross change	Wound index
Complete healing of wounds	0
Incomplete but healthy healing of wounds	1
Delayed healing	2
No instigation of healing but the environment is healthy	3
Pus formation: prove of necrosis	4
Total	10

III. Results & Discussion

A. Characterization of the biosurfactant

The Molisch's test and FTIR study indicated it as rhamnolipid. Bands from FTIR analysis at 1162 cm^{-1} and 1054 cm^{-1} signified the presence of C-O stretching in ester and carboxylic group. Bands at 1461, 1375 and 1226 cm^{-1} were due to deformation of C-H and O-H present in carbohydrates [8].

B. Measurement of wound closure

Healing of wound in the shortest possible time is the most important aim of wound management study. The time requirement for wound healing was significantly lower for RL and FS groups than NC and OB groups. At 4th day a blood clot associated with cell debris was found with dark red colour for all the groups, which indicated a beginning of the healing process with no swelling, redness and microbial infection in RL and FS groups. But the NC group showed inflammation, infection and pus formation at the wound site. At 10th day, complete wound closure for both the RL and FS groups demonstrated complete healing and granulation tissue formation but there was still an open wound for NC and OB group.

From figure 1 we find that RL group exhibited good reduction of wound area in comparison to NC group.

Percentage of wound contraction after 10 days (Table 2) exhibited the healing effect of RL group (~96%) and FS group (~97%) were found to be significant compared to NC group (~75%). The healing process involves contraction, narrowing and ultimate closing of the wound. The healing

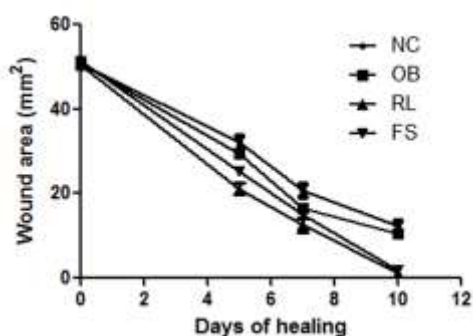


Figure 1 Area of wound closure on 0th, 5th, 7th and 10th day respectively.

process involves contraction, narrowing and ultimate closing of the wound. Complete healing of RL and FS group was achieved after 10 days. Stipcevic et al. [12] reported that di-rhamnolipid could assist the process of burn wound re-epithelization in their study in 35 days. The mean wound indexes of RL and FR group were comparable

C. Evaluation of wound index and tensile strength

Collagenesis was the main criteria for expressing the quality of biosynthesis and deposition of the newly formed collagen in terms of tensile strength (Table 2) [13]. Higher tissue tensile strength of the RL group suggested that enhanced collagen maturation occurred due to increased cross-linking of collagen fibers [14]. So, the significantly greater tensile strength of the RL group indicated better healing than the other groups.

D. Histopathology

Histology of regenerated rat skin after 10 days treatment exhibited the tissue regenerative efficacy of RL as shown in Fig. 3. Histological features of NC group (Fig. 4a) showed that the epidermis was not developed, acute inflammatory cells were present, very few blood vessels were present and the dermal region lacked hair follicles or vacuoles which indicated absence of well developed regenerated tissue. Large number of scar formation was present in the dermis layer of skin. Though the epidermis was formed in OB treated rats (Figure 4b) but the hair follicles and sebaceous glands were absent, the dermis was full of scar tissue which indicated poor re-epithelisation. The RL treated group (Figure 4c) exhibited normal epidermis with thick layer of

Table 2 Tensile strength, wound index and % wound contraction of different treatment groups. N=6, X±SEM, ^aP<0.05, ^bP<0.05 and ^cP<0.05 were compared to NC, OB and FS group respectively.

Treatment groups	Percentage wound contraction	Wound index	Tensile strength (g)
NC	74.00±2.49	3.0±0.37	251.83±3.38
OB	78.85±3.85 ^a	2.33±0.33 ^a	326.67±4.46 ^a
RL	97.39±1.57 ^{a,b,c}	1.33±0.21 ^{a,b,c}	409.67±4.07 ^{a,b,c}
FS	96.49±1.67 ^{a,b}	1.17±0.17 ^{a,b}	408.67±6.33 ^{a,b}

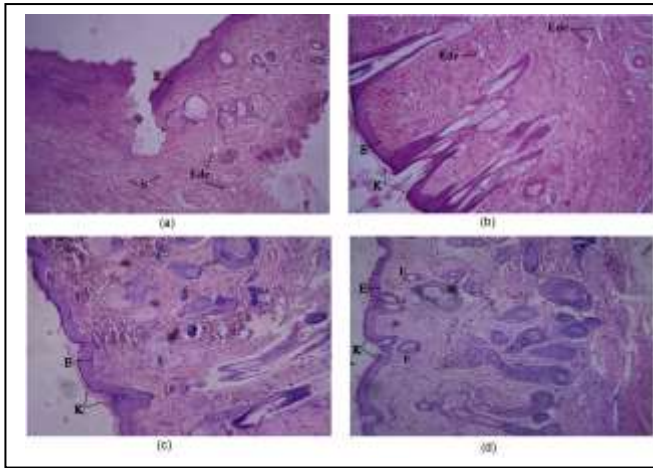


Fig 2 Histology of skin at day 10 stained with H&E.

keratinocyte on surface. Similar results were shown by Stipcevic T et al (42) as they reported that di-rhamnolipid stimulated the proliferation of keratinocyte in case burn wound healing.

In case of FS group (Figure 4d), the hair follicles were not so developed but epidermis layer, keratinocyte formation and other features were well developed similar to RL group. Thus in a nutshell, rhamnolipid produced by *P. aeruginosa* DSM 50071 using *Catla catla* fish fat can become a significant alternative of traditional antibiotic for wound healing which was established by analysis of different physical parameters and confirmed by histological studies.

Acknowledgment

The work was funded by University Grant Commission, India.

References

- [1] Buchanan, S., Gaylinn, S., 1992. CRB Commodity Year Book. Knight-Ridder FinancialPublishing, New York.
- [2] Jarvis FG, Johnson MJ. A glyco-lipide produced by *Pseudomonas aeruginosa*. J Am Chem Soc 1949;71:4124-4126.
- [3] Stipcevic T, Piljac A, Piljac G. Enhanced healing of full thickness burn wounds using di-rhamnolipid. Burns 2006;32:24-34.
- [4] Singer AJ, Clark AF. Cutaneous wound healing. N Engl J Med 1999;341:738-746.
- [5] Leaper DJ, Gottrup F. Wounds: Biology and management. In: Leaper DJ, Harding KG, editors. Surgical wounds. Hong Kong: Oxford University Press, 1998:23-40.
- [6] Metz CN. Fibrocytes: a unique cell population in wound healing. Cell Mol Life Sci 2003;60:1342-1350.
- [7] Varoglu E, Seven B, Gumustekin K, Aktas O, Sahin A, Dane S. The effects of vitamin e and selenium on blood flow to experimental skin

burns in rats using the ^{133}Xe clearance technique. Cent Eur J Med 2010;5:219-223.

- [8] Sana S, Bhattacharya M, Datta S, Biswas D. RSM study for the production of rhamnolipid using *Catla catla* fish fat. Int J Curr Microbiol App Sci 2015;4:169-178.
- [9] Auddy RG, Abdullah MdF, Das S, Roy P, Datta S, Mukherjee A. New guar biopolymer silver nanocomposites for wound healing applications. BioMed Research International 2013;2013:1-8.
- [10] Biswas TK, Maity LN, Mukherjee B. Wound healing potential of *Pterocarpus santalinus* Linn: a pharmacological evaluation. Int J Low Extrem Wounds 2004;3:143-150.
- [11] Ziv-Polat O, Topaz M, Brosh T, Margel S. Enhancement of incisional wound healing by thrombin conjugated iron oxide nanoparticles. Biomaterials 2010;31:741-747.
- [12] Stipcevic T, Piljac T, Isseroff RR. Di-rhamnolipid from *Pseudomonas aeruginosa* displays differential effects on human keratinocyte and fibroblast cultures. J Dermatol Sci 2005;40:141-143.
- [13] Agarwal PK, Singh A, Gaurav K, Goel S, Khanna HD, Goel RK. Evaluation of wound healing activity of extracts of plantain banana (*Musa sapientum* var. paradisiaca) in rats. Indian J Exp Biol 2009;47:32-40.
- [14] Udupa AL, Kulkarni DR, Udupa SL. Effect of Tridax procumbens extracts on wound healing. Int J Pharmacogn 1995;33:37-40.

About Author (s):



Santanu Sana studied Pharmacy at the West Bengal University of Technology, receiving his B.Pharm degree in 2004 and M.Pharm in 2010, respectively. Currently he is doing his Ph.D. under the guidance of Prof. Sriparna Datta from the University of Calcutta. He is a life member of Indian Science Congress. His main research interest lies in the utilization of waste for biosurfactant production and its significant application.



Sriparna Datta studied Chemistry and Pharmaceutical Technology at the University of Calcutta. She also received her Ph.D. from Calcutta University. Besides more than 19 years teaching experience she has 13 years industrial experience. She is a member of the Royal Society of Chemistry, Indian Chemical Society, Institute of Chemical Engineers and Indian Pharmaceutical Association. Her research focuses is on Bioremediation and other fields of Microbiology and also developing Novel transdermal gel formulations for curing experimental arthritis.