

Effects of smokeless tobacco on the granulosa cells of the ovaries of non-pregnant female Swiss albino rats- A Histological study

Syna Pervaiz Singha¹, Afroz Saleem Kazi², Usha Isaac³

Abstract-

Background: The use of tobacco has been linked with a higher mortality rate. Smokeless tobacco also contains higher quantities of nicotine. Low fertility rates & adverse reproductive outcomes are associated with tobacco use. An effort is made to evaluate the effects produced by the locally available brand of smokeless tobacco on the granulosa cells of the ovaries of the female Swiss albino rats.

Material and methods: 30 adult female Swiss albino rats were randomly selected. They were equally divided into three groups. Group A were taken as control. Group B&C consisted of experimental groups which were given 5 %& 10% of locally available brand of smokeless tobacco in their feed. The feed and water were given ad libitum. On 31st day, animals were sacrificed and their ovaries were removed. The specimens were processed for the purpose of light microscopy using H & E and trichrome stains.

Results: Ovaries of both B & C groups showed significant increase in the number of cystic follicles, apoptotic cell death and necrosis in the granulosa cells (P value ≤ 0.001).

Conclusion: This study concluded that the smokeless form of tobacco causes adverse effects on the granulosa cells of the ovaries of the female Swiss albino rats.

Keywords: granulosa cells, nicotine, ovaries, reproduction, side effects, smokeless tobacco.

I. Introduction

Tobacco use is the leading cause of morbidity and mortality worldwide. These states have been attributed to a number of tobacco related conditions, including heart disease, malignancies, chronic pulmonary disease and stroke.^[1]

Dr. Syna Pervaiz Singha
Assistant Professor
Isra University Hyderabad.
Sindh, Pakistan

By the end of 19th century, tobacco was used in relatively small proportions.

But a number of factors contributed to the 20th century surge in its use.

The arrival of mass media made possible the extensive advertisement of tobacco use.

Initially men were the only targets but with the rise of women's liberation there was encouragement of women's use of tobacco as well.^[2]

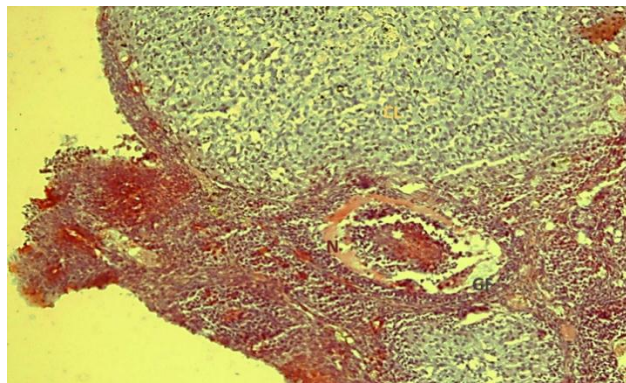
Dread of long term illness, lead to the dereliction of tobacco in cigarette form. Another set of users developed who use smokeless tobacco in chewable form.^[3]

Researches carried out to examine the data of the adverse effects of tobacco use indicated that most people are aware of the relationship between use of tobacco products and cancers but less than one-half of those surveyed appreciated its association with other disorders like heart conditions, infertility and negative outcomes of pregnancy.^[4]

Studies conducted on women in the region of South Asia with an aim to find the prevalence of nicotine abuse in the rural community have concluded that due to easy accessibility and lack of awareness regarding the tobacco products there is an increased intake of smokeless tobacco products.^{[5],[6]}

Tobacco has been related with damage to the process of folliculogenesis. Ovarian tissue has been able to retain the toxic compounds present in tobacco thus leading to the consequences of follicle loss, abnormal follicle growth and impairment of morphology and oocytes maturation.^[7]

II. Material and methods



removed. The tissue were then processed for histological examination under light microscopy using H & E and Trichrome stains.

III. Statistical analysis

The histological changes in the ovaries were analyzed using SPSS version 16.0. The changes between the Groups were also analyzed using Student's - T test.

IV. Result

The use of oral form of smokeless tobacco produced marked effects on the ovaries of the albino rats. When the ovarian tissue of the rats comprising of the three groups was examined using H & E stain significant changes were noticed. (Fig No. 1). The no. of corpora lutea in group B & C was markedly reduced as compared to Group A. Apoptosis in the granulosa cells was visible in both Group B & C. Multiple degenerated granulosa cells characterized by vacuolated cytoplasm and dense nuclei were also seen in the Group C.(p value < 0.001)

Histological study of the tissues of Group C under Trichrome stain showed marked fibrosis around the graffian follicle which was accompanied by necrosis in the granulosa cells of the follicles (photomicrograph a, b &c)

V. Discussion

This study showed significant histological changes in the ovarian tissue. Few mature graffian follicles and decreased number of corpus luteum are also suggestive of the same findings. [8], [9]. The primordial follicles and follicular growth appears to be sensitive to the components of tobacco. Degenerative and atrophic changes were observed in the granulosa cells. There were marked vacuolations appearing in the ovarian stroma. The apoptotic changes were also visible in the granulosa cells. [7]

This research also suggests that ovarian tissue retains tobacco compounds leading to the consequences of follicular loss, follicular atresia and necrotic changes in the granulosa cells. [7]

VI. Conclusion

Based on the histological findings in this study it can be easily stated that the exposure to the oral smokeless tobacco alters every stage of folliculogenesis.

VII. Recommendation

Since most of the users have had their first encounter with the tobacco at a much younger age, the efforts regarding education, prevention and cessation should be put forth at a much earlier age. Furthermore effects of the smokeless form of tobacco on the fertility rate and the pregnancy outcomes should also be carried out

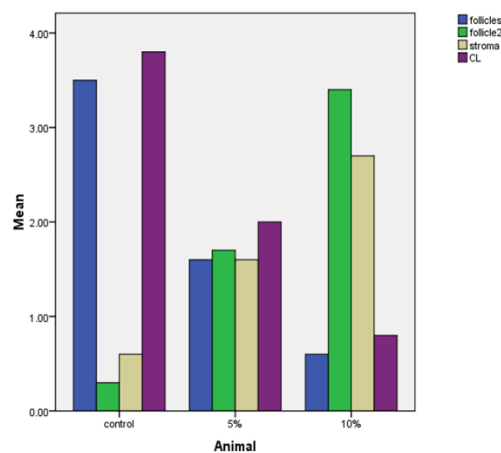
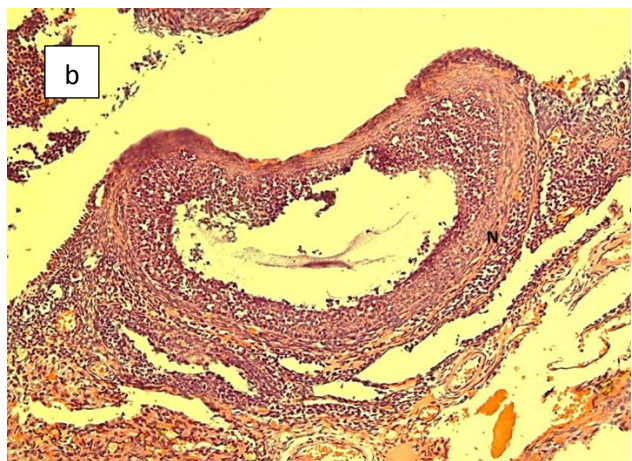


Fig No. 1: Comparison of histological findings of ovaries of rat of control , Group B (5%) and Group C (10%).

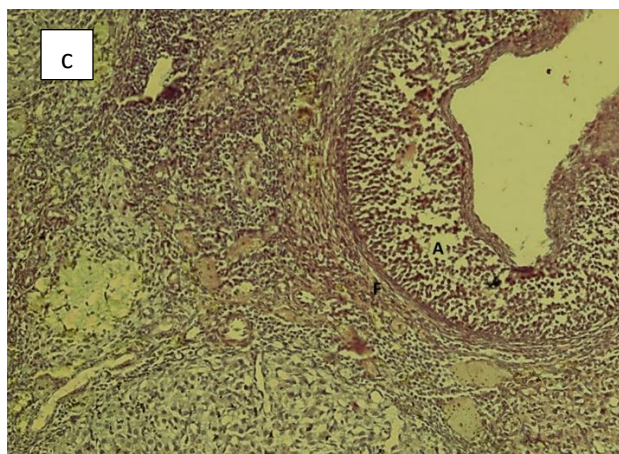
■ : Healthy follicles ■ : atretic follicles
 ■ : Stromal change ■ : corpora lutea p-value < 0.05



Photomicrograph a: Granulosa cells of Group C showing necrosis in the graffian follicle (Trichrome x 40)



Photomicrograph b: showing necrosis (N) in graffian follicle of Group C under Trichrome staining x 40



Photomicrograph c showing apoptosis (A) & fibrosis (F) in granulosa cells Group C (Trichrome x 40)

References

- [1] Iranloye, B.O and Bolarinwa, A.F. (2009). Effect of nicotine administration on the weight and histology of some vital organs in female albino rats. *Niger. J. of Physiological sciences*. Vol 24(1):7-12.
- [2] Gupta ,P.C and Ray, C.S (2003) Smokeless tobacco and health in India and South Asia *Journal of Respiriology*, Vol. 8, pp. 419–431.
- [3] Stanfill, S.B., Connolly, G.N., Zhang, L., Jia, L.T., Henningfield, J.E., Richter,P., Lawler, T.S., Ayo-Yusuf, O.A., Ashley, D.L and Watson CH(2010) Global surveillance of oral tobacco products: total nicotine, unionised nicotine and tobacco-specific N-nitrosamines. *Journal of Tobacco Control*, Vol.20, No. 3, pp.1136-1137.
- [4] Warren CW, Jones NR, Peruga A, Chauvin J, Baptiste J-P, Costa de Silva V, et al Global youth tobacco surveillance, 2000–2007.MMWR Surveill Summ. 2008; 57:1–21.
- [5] Srivastava, M., Parakh, P and Srivastava, M. (2010) Predictors and prevalence of nicotine use in females: a village-based community study *Indian Journal of Psychiatry*, Vol.19, pp. 125-129.
- [6] Shrestha, J., Shanbhag, T., Shenoy, Smita ., Amuthan, A., Prabhu, K., Sharma, S., Banerjee, S and Kafle, S (2010) Antiovulatory and abortifacient effects of Areca Catechu (betel nut) in female rats. *Indian Journal of Pharmacology*, Vol. 42, No. 5, pp. 306-311.
- [7] Jurisicova A, Taniuchi A, Li H, Shang Y, Antenos M, Detmar J, Xu J, Matikainen T, Benito HA, Nunez G et al.Maternal exposure to polycyclic aromatic hydrocarbons diminishes murine ovarian reserve via induction of Harakiri. *J Clin Invest* 2007; 117:3971–3978
- [8] Mulligan, T.A.M., Stampfli, M., Foster, W.G (2009). Cigarette smoke causes follicle loss in mice ovaries at concentrations representative of human exposure. *J. of Hum Reprod*; Vol 24: 1452-1459.
- [9] Neal MS, Zhu J, Foster WG. Quantification of benzo[a]pyrene and other PAHs in the serum and follicular fluid of smokers versus non-smokers. *Reprod Toxicol* 2008; 25:100–106.