

Synergetic neuro-protection of hippocampal neural cells in rats supplemented choline and Docosahexaenoic acid prior to cerebral hypo-perfusion injury

[Kiranmai S Rai^{1*}, Sivakumar.G², Divya P³]

Abstract: Cerebrovascular disease risk including stroke is projected as the second most frequent cause for death/disability by year 2020. Preventive measures to minimize stroke related hippocampal cognitive impairment in high risk group gains least attention among health-care professionals. Several studies establish the critical importance of essential dietary components choline and Docosahexaenoic acid [DHA] as neuronal membrane phospholipid precursors that maintain cognitive states in health and in neurological disorders. There are no studies exploring the synergetic neuro-protective potential of choline and DHA in attenuating hippocampal neural deficits in stroke-risk group. The present study explores synergetic neuro-protective potential of choline and DHA supplemented to Wistar rats prior to hypo-perfusion ischemic brain injury. 10 month-old male Wistar rats were subdivided into 4 groups [n=8 /group]-Normal control group [NC], Bilateral common carotid artery occlusion group [BCCAO], Sham BCCAO group and Choline- DHA supplemented group [Prophylactic Choline-DHA BCCAO / preCholine-DHA group]. Choline and DHA were orally supplemented to preCholine-DHA group of rats for fifteen days prior and forty days subsequent to permanent surgical bilateral occlusion of common carotid arteries, inducing chronic global cerebral hypo perfusion injury. All groups of rats were tested for cognition and subsequently sacrificed to study hippocampal neural cells by cresyl staining. Microscopic examination of cresyl stained hippocampal sections from ischemic brain injured rats shows significant neural cell deficits in CA1, CA2, CA3 and CA4 regions compared to the same in age-matched sham BCCAO and NC rats. Supplementation of both Choline-DHA prior to ischemic stroke in rats significantly increased survival of neural cells in these regions as compared to the same in age-matched non-supplemented BCCAO rats. Combined supplementation of both choline and DHA prior to ischemic brain injury in stroke-risk group, protects hippocampal neural cells and minimizes cognitive impairment.

Key words: Chronic cerebral hypoperfusion brain injury, Combined Choline-DHA therapy, Hippocampal neural cells, synergetic neuroprotection.

*Corresponding author :

1*.Prof. Kiranmai S Rai PhD
Department of Physiology, Melaka Manipal Medical College,
Manipal University, Manipal, Karnataka, India.
Phone :0820 2522519,8277032951

2 and 3. Siva Kumar G and Divya P
Department of Physiology, Kasturba Medical College,
Manipal University, Manipal, Karnataka, India.

I. Introduction

Cerebrovascular disease risk including stroke is projected as the second most frequent cause for death/disability by year 2020 [1-5]. Cerebral ischemic cascade involves

multiple complex biochemical pathways that cause injuries to neural cells resulting in devastating effects including neural cell death, a prerequisite for irreversible motor and cognitive functional deficits. Hence, therapeutic strategies involving a single biochemical entity may not effectively attenuate ischemic neural cell injuries. Focus of current therapeutic strategies for ischemic stroke is mainly aimed to have maximum motor recovery rather than focussing on preventive neuro-protective measures to reduce neural injuries by prophylactic therapies that will minimize stroke risk eventualities [2]. Very few studies have explored prophylactic synergetic dietary supplementation strategies that have the potential to simultaneously sustain and protect neural cells from effects of cerebral ischemia. Moreover in the event of a stroke, these dietary constituents may help protect neural cells to sustain the deleterious effects of ischemia-induced onslaught from molecules accumulating at the site, as these dietary constituents have the potential to simultaneously target multiple complex biochemical pathways in the ischemic cascade. Dietary choline and docosahexaenoic acid (DHA) are two such essential neuronal membrane phospholipid precursors, known to be important in sustaining and enhancing cognitive functions. Choline is richly present in dietary components like egg yolk, beef and chicken meat, soybean oil, and also available as an oral supplement. Choline a relatively non-toxic inexpensive compound is a quaternary amine (trimethyl- β -hydroxy-ethylammonium) predominantly utilized for the synthesis of phosphatidyl choline (PtdCho) in liver and brain that may be otherwise synthesized *de novo* by PEMT enzyme activity [6-9].

Choline is as a precursor for the biosynthesis of neural and sub-neural membrane phospholipids like phosphatidyl choline and sphingomyelin.

Moreover, acetylcholine synthesis, metabolism and concentration in the brain depends more upon the availability of choline rather than the enzyme choline-acetyl transferase. Cholinergic neurons in the brain, store a large pool of choline as phosphatidylcholine and other choline-phospholipids are available for acetylcholine synthesis when required [9]. In addition, these neurons have a dynamic balance for utilization of choline in the two metabolic pathways that involves synthesis of PtdCho and acetylcholine [10-11]. These two pathways compete for the available choline, with acetylation being favoured when neurons are physiologically active [11] and if ACh becomes depleted due to glutamate excite-toxity as in cerebral ischemia, choline phospholipids, especially PtdCho, is hydrolyzed to provide a source of choline. This phenomenon is called as auto-cannibalism [11-12]. It is a well-known fact that the central cholinergic system plays a

crucial role in learning and memory [13] and any disruption to this system would lead to cognitive deficits.

Additionally neural cell membranes also contain lipids concentrated in amino phospholipids, including chiefly essential omega-3 PUFA's like DHA and EPA [14-15]. Pre-injury supplementation of DHA is shown to reduce injury response and improved memory compared to non-DHA supplemented group in a rodent model of traumatic brain injury [15]. Moreover a recent study has also shown that DHA depleted (70% loss) mice of third generation with traumatic brain injury exhibited significant slower motor, cognitive and structural neuronal recovery compared to age matched controls [16].

We hypothesize that prophylactic synergetic dietary supplementation of choline and DHA prior to a cerebral ischemic event like stroke will strengthen neural membranes and have the potential to enhance the ischemic threshold of neural cells by providing effective neuro-protection against ischemic damage, minimizing neural cell deficits and as an outcome reducing post stroke functional deficits.

Based on earlier research findings, the present study was designed to test our hypothesis of prophylactic synergetic neuro-protection in stroke. In the present study the efficacy of prophylactic supplementation of both Choline and Docosahexaenoic acid (DHA) on hippocampal neural cell viability and deficits subsequent to chronic cerebral ischemic injury in rat, were observed.

Objective

To study the synergetic neuro-protective role of prophylactic dietary choline and DHA supplementation to Wistar rats, on post-stroke hippocampal neural cell viability.

Materials and Methods

Animals:

8-12 month old Male Wistar rats (250-300 g) were used for the study. Animals were maintained under standard laboratory conditions with free access to food and water *ad libitum*. Studies were carried out in accordance with guidelines given by the Committee for the Purpose of Control and Supervision of Experiments on Animals (CPCSEA), New Delhi (India) and subsequent to approval by the Institutional Animal Ethical committee of KMC, Manipal University, India (IAEC/KMC/66/2010-2011).

Male Wistar Rats (n=8 /group) were randomly allocated to the following groups- Normal control rats [NC]; Sham Bilateral Common Carotid Artery Occlusion rats [Sham BCCAO] that underwent a sham surgery and were administered identical volumes of physiological saline solution orally instead of any dietary supplement; Bilateral Common Carotid Artery Occlusion [BCCAO] surgery inducing chronic cerebral ischemic brain injury in rats and Prophylactic Choline + DHA supplemented BCCAO rats that were orally supplemented with choline chloride [4.6mmol/kg/bodyweight /day] and DHA 300 mg/kg/day via oral gavage for 15 days as pretreatment and continued after the induction of BCCAO surgery till they were euthanized for observing and analyzing neuronal morphology.

Induction of Chronic cerebral hypoperfusion ischemic injury:

Chronic cerebral hypo-perfusion ischemic brain injury was induced in Wistar rats as described by Seul Ki Kim *et al*, [17]. 12 h prior to surgical procedure food was withdrawn and water was supplied *ad-libitum*. Briefly, animals assigned to BCCAO surgical group were anesthetized with ketamine (50mg/kg b.w IP)- xylazine (5mg/kg b.w IP) with atropine sulphate (130mg/Kg b wt) and gentamycin(4.4mg/kg) as pre-anesthetic medication. Subsequent to expose of the common carotid arteries, both were double ligated with silk suture permanently to deprive blood supply to brain completely via carotid/anterior circulation.

In sham-operated group of rats, with the exception of occlusion of these arteries, surgical procedures were similar to those in the BCCAO-operated rats.

Appropriate postoperative care was provided to all surgically operated rats as described by Seul Ki Kim *et al* [17]. Subsequent to recovery period all experimental animals were assessed for cognitive efficacy [data previously published] and later sacrificed for processing the brains to observe and assess hippocampal neural cell viability.

Processing of brain tissue for cresyl violet / Nissl staining

Rats from all afore mentioned groups were deeply anesthetized with high doses of ketamine-xylazine injection IP. All rats were trans-cardially perfused with equi-volumes of heparinized saline and 10% formalin. After perfusion, rats were decapitated and their brains were removed and embedded in paraffin blocks according to standard protocols. 5µm thick coronal sections of brains were cut using rotary microtome. These sections were then serially collected on to albumin coated slides and kept on the slide warmer.

Approximately every 10-15th best section per rat brain in the series was chosen for Nissl staining. Selected sections were immersed in 0.1% cresyl violet at 37^oC for 20 min. After rinsing with distilled water, sections were dehydrated, mounted with DPX and cover slips were applied. Sections were then examined under a light microscope. Nissl staining method was used for evaluation of morphology of neural cells.

Assessment of neural cell viability in the Hippocampus

Overall viability of neurons in the hippocampus were examined under 40 x objective of the light microscope and morphological assessment of neural cell alterations /deficits were observed specifically in CA1, CA2, CA3, and CA4 sub-regions of hippocampus. Surviving neural cells appeared rounded with palely stained nuclei whereas non-surviving neural cells appeared dense, irregularly shaped and shrunken with pyknotic nuclei. Neuronal morphology and the number of pyknotic neurons were compared and analyzed between NC, BCCAO and prophylactic choline and DHA supplemented BCCAO groups from representative photomicrographs.

Statistical Analysis: Grid and photo-micrographic representation of data was performed using camera fixed

to the microscope & subsequently processed with Adobe Photoshop.

Results

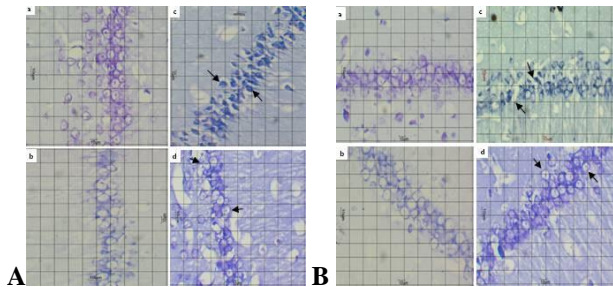


Fig-1A,B: Representative photomicrographs of CA1 and CA2 regions of the Hippocampus in rat groups-a) Normal Control, b) Sham BCCAO-Sham control, c) BCCAO- Bilateral common carotid artery occlusion and d) Choline+ DHA Suppl. BCCAO-Prophylactic combined choline and DHA supplemented to BCCAO rats (n=8 / group). Scale grid=10 μ m.

Note: Arrow in Fig 1A c represents hyper-dense dead CA1 neurons in BCCAO group and in Fig 1Ad represents viable CA1 neurons in Choline + DHA Suppl. BCCAO group where-as arrow in Fig 1Bc represents non-surviving shrunken CA2 neurons with pyknotic nucleus in BCCAO group and in Fig 1Bd represents surviving CA2 neurons in Choline + DHA Suppl. BCCAO group.

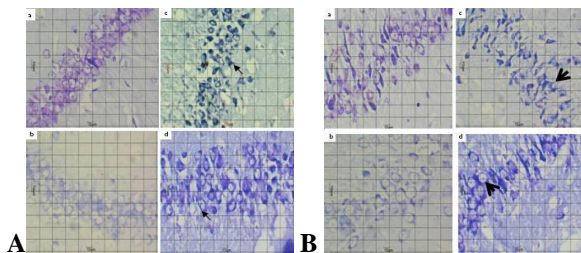


Fig-2A,B: Representative photomicrographs of CA3 and CA4 regions of the Hippocampus in rat groups-a) Normal Control, b) Sham BCCAO-Sham control, c) BCCAO- Bilateral common carotid artery occlusion and d) Choline + DHA Suppl. BCCAO-Prophylactic combined choline and DHA supplemented to BCCAO rats (n=8 / group). Scale grid=10 μ m.

Note: Arrow in Fig 2Ac represents irregularly shaped hyper-dense non-viable CA3 neuronal cell bodies in BCCAO group and in Fig 2Ad represents clear spherical or pyramidal shaped viable and surviving CA3 neurons in Choline + DHA Suppl. BCCAO group where-as arrow in Fig 2Bc represents irregularly shaped non-viable CA4 neuronal cell bodies in BCCAO group and in Fig 2Bd represents few of the surviving CA4 neurons in Choline +DHA Suppl. BCCAO group.

Qualitative analysis of hippocampal neuronal cells:

Nissl stained brain sections were microscopically screened and selected for qualitative assessment of overall viability of neural cells in hippocampal sub regions.

CA1 region of the hippocampus:

Fig1A shows representative photomicrographs of CA1 sub region of the hippocampus. CA1 region in hippocampal sections were observed to have clear and intact 2 – 3 layers of rounded/pyramidal neuronal cell bodies in both normal control [Fig 1A a] and sham BCCAO group [Fig 1A b] of rats. Alternately, significant neuronal damage

with shrunken neuronal cell bodies, hyper dense neuronal soma and few pyknotic nuclei were observed in hippocampal sections from BCCAO rats induced with chronic cerebral hypo-perfusion ischemic brain injury [Fig 1A c] as compared to the same in age matched normal and sham BCCAO rats. Supplementation of combined Choline and DHA prior to BCCAO surgery in rats [prophylactic group] was observed to have better preserved neuronal cell viability [Fig1Ad] compared to the same in age matched BCCAO groups of rats.

CA2 region of the hippocampus:

CA2 region of the hippocampus is considered as a transition zone between CA1 and CA3 sub regions. Microscopic examination of the representative photomicrographs of hippocampal CA2 sub region Fig 1B (a, b, c and d) shows a reduction in the number of neuronal cell layers and cell size in hippocampal sections from BCCAO rats [Fig 1B c] compared to the same in NC, Sham BCCAO [Fig 1B a, b]. Supplementation of combined Choline and DHA prior to BCCAO surgery in rats [prophylactic group] was observed to have better preserved neuronal cell viability [Fig 1B d] compared to the same in age matched BCCAO groups of rats.

CA3 region of the hippocampus:

Compared to other regions of the rodent hippocampus, CA3 sub region is quite broad and has approximately 4 -5 layer of pyramidal cells and are more vulnerable to stress. Microscopic examination of CA3 region from representative photomicrographs Fig 3 (a, b, c and d) of hippocampal sections of Normal control, Sham BCCAO group of rats [Fig 2A a, b] were observed to have clear spherical or pyramidal shaped viable neuronal cells with distinct nucleus, cytoplasm and cell membrane, forming 4-5 layers. Also these neurons appeared to be relatively densely packed with minimal inter-cell distance. Contrarily, CA3 neuronal cells from hippocampal sections of BCCAO group of rats [Fig 2A c] were observed to have lesser cell density, with shrunken, irregularly shaped hyper-dense cells and almost no distinct boundary between nucleus and cytoplasm. Additionally, layers of CA3 neuronal cells in BCCAO group were observed to have relatively more spaces between them indicating the reduced cell size or cerebral edema. Alternately BCCAO rat group with prior supplementation of choline and DHA was observed to have fewer dead cells and better preserved CA3 neuronal cell morphology [Fig 2A d].

CA4 region of hippocampus:

CA4 sub-region of the hippocampus is interposed between the two blades of dentate gyrus with 4-5 layers of scattered neuronal cells, less densely packed. In the present study, microscopic examination of neural cells in the CA4 sub-region of the hippocampus [Fig 2B (a, b, c and d)] was observed to have significant neuronal damage in brain sections from BCCAO group of rats [Fig 2B c] with least cell density as compared to the same in age matched NC and Sham BCCAO rats. Prophylactic supplementation of combined choline and DHA to rats preserved CA4 neuronal cells [Fig 2B d] to a small extent although many CA4 neural cells appeared to be non-viable.

Discussion

Extensive studies on Wistar rat model of BCCAO have clearly documented that occlusion of carotid arteries on both sides deprives blood supply completely to anterior and partially to middle cerebral arteries causing injuries to forebrain, amygdale, hippocampus and white matter lesions and gliosis in frontal, parietal and temporal lobes with degenerative changes in hippocampus [18].

In our present study, histo-pathological screening of cresyl stained brain sections from Wistar rats with BCCAO induced cerebral hypo-perfusion injury clearly confirms extensive neurodegenerative changes in CA1, CA2, CA3, and CA4 sub-regions as documented in earlier studies [18]. Further studies on vulnerability of different sub regions of hippocampus to ischemia indicates that even a brief period of transient ischemia causes damage to CA1 region and prolonged global cerebral hypo-perfusion in gerbils kills almost 96% of CA1 neurons by the fourth day. Alternately, CA3 and few other inter-neurons of hippocampus are relatively resistant to acute transient ischemia but susceptible to long term hypo-perfusion [19]. The degeneration of CA1 interneurons and CA3 pyramidal cells may also occur secondary to ischemia-related delayed neuronal cell death of CA1 pyramidal neurons [20]. However, some interneurons of the hippocampus, like somatostatin positive interneurons located in the dentate hilus [21], calretinin-positive interneurons in the CA3 area [20] are relatively less sensitive to ischemia than other neurons of the same region. Moreover, it is observed that transient ischemia stimulates proliferation of neurons in CA1 region [22] as well as in subgranular zone of dentate gyrus [23].

Based on hippocampal slice studies, it is also observed that the intactness of neurons of various hippocampal sub-regions with their complex cortico-hippocampal loop circuits is essential for normal spatial learning and memory [24].

In our current study, examination of representative photomicrographs from randomly selected sections shows that prophylactic combined choline and DHA supplementation to BCCAO rats prevents neuro-degeneration and improved neuronal survival and density in CA1, CA2, CA3 and CA4 regions of hippocampus compared to non-supplemented BCCAO rats.

This is consistent with earlier studies on forebrain ischemic brain injured gerbils supplemented with CDP-choline, where it was found that choline moiety of CDP-choline and not cytidine was involved in neuro-protection of hippocampal CA1 region compared to the same in untreated transient forebrain ischemic gerbils [25]. Earlier studies on rat model of traumatic brain injury (TBI) treated with CDP-choline also reported reduced hippocampal neuronal damage in CA2 and CA3 sub-regions, cortical contusion volume, and neurological dysfunction in rats [26]. A recent study shows that third generation DHA depleted mice on traumatic brain injury were observed to have poor motor and cognitive recovery with exacerbated neuronal death, reduced NeuN positive cells compared to normal mice [16]. Alternately, dietary supplementation with DHA prior to traumatic brain injury reduces injury response, as measured by axonal injury counts, apoptosis,

and memory assessment by water maze testing [15]. Moreover, Wurtman RJ et al [27] have observed that consumption of DHA, choline, and uridine monophosphate in combination resulted in large improvements in hippocampal based memory function and increased neuron phosphatide levels. Similarly other studies have shown that rats with cerebral ischemia supplemented with fish n-3 fatty acids (DHA and EPA) along with their regular food had significantly reduced tunnel positive apoptotic neurons in CA1, CA2, CA3 and dentate gyrus hippocampal sub-regions compared to the same in untreated rats [28]. Further, studies also report that oral pre-treatment with ethyl-DHA significantly attenuates ischemia- reperfusion induced delayed neuronal death in CA1 sub-region of gerbil hippocampus [29].

Moreover, studies have also shown that a higher choline intake increases PEMT activity resulting in greater PC-DHA enrichment of the PC molecule [30] whereas higher DHA intake in the absence of PEMT activity as in PEMT -/- mice influences PC- DHA, PS-DHA and PI- DHA levels that restores fetal hippocampal neurogenesis [31]. Thus with increased prophylactic availability of both choline and DHA and greater PC-DHA enrichment of the PC molecule, neural membranes may be largely better stabilized to withstand injurious effects of chronic cerebral hypo-perfusion and promote neuronal repair by enhancing neural plasticity and neurogenesis that may help attenuate cognitive deficits. Moreover, the role of prophylactic combined choline and DHA supplementation in providing neuro-protection to attenuate vascular cognitive impairments in ischemic brain injured rats are also supported by some of the following research studies.

Prior supplementation of both Choline and DHA increases the source of substrates for neural cell membrane biosynthesis in injury-induced neurogenesis of SGZ of DG [32], CA1 and other sub regions. This helps to restore complex circuits of hippocampus as well as normal neural signaling thereby improving functionality of hippocampal based spatial learning and memory [22].

Further, metabolites of choline and DHA augment brain antioxidant mechanisms with neuro-protectin D1 thereby preventing neuronal damage and damage to synapses of cortico-hippocampal loop during ischemic cascade [13, 33].

Studies also show that ischemic biochemical cascade leads to glutamate excite-toxicity that depletes ACh that causes choline to be derived from hydrolyzing neuronal membrane phospholipid [PtdCho] by 'auto-cannibalism'. Thus, exogenous choline supplementation helps to replenish brain ACh levels during ischemic cascade induced excite-toxicity and prevents the need for auto cannibalism and increased destruction of neural cells [11].

Conclusion

Post stroke vascular cognitive impairment is more common than the recurrence of stroke itself. Compared to rehabilitation for motor deficits, prophylactic and preventive strategies for management of post-stroke cognitive impairment and neuronal cell loss gain least attention even among health care professionals. Results of our present study confirms the need for supplementing two

important neural membrane phospholipid precursors-Choline and DHA that prevents the risk of post stroke vascular cognitive impairment by providing synergetic neuro-protection to hippocampal neural cells and preventing neuronal deficits.

Thus, prior dietary supplementation of both choline and DHA to high-risk population predicted for cerebrovascular events is an easy and cost effective method to provide synergetic neuro-protection to vulnerable hippocampal neurons. Combined prophylactic dietary supplementation may also benefit patients undergoing coronary artery bypass grafting surgery, carotid endarterectomy, endovascular therapy and cardiac valvular replacement surgeries, who are at risk of developing ischemic brain injury complications during the procedure particularly to the neurons of hippocampus. Patients with chronic underlying modifiable stroke risk factor disorders such as hypertension, atherosclerosis and metabolic syndrome may also benefit from prophylactic dietary combined supplementation of choline and DHA against early mild cognitive deficits.

Further, large scale clinical trials and population-based studies are needed to ascertain the true advantage of these dietary supplements in at-risk groups for meaningful public health benefits. Subsequent to confirmatory studies, both DHA and Choline may be fortified in regular health drinks to supplement the high risk population.

Acknowledgements: We thank Gowri Mahohari for assistance in BCCAO surgery and Manipal University for providing all facilities to support this study.

References:

- [1] Dalal PM: Burden of stroke: Indian perspective. *Int J Stroke* 2006;1:164-166.
- [2] Murthy J. Thrombolysis for stroke in India: Miles to go..... *Neurol India* 2007;55:3-5
- [3] World Health Organisation. Measurement in health. Statistics Tables 2009
- [4] Fiona C Taylor, Suresh Kumar-Stroke in India Factsheet (updated 2012)
- [5] Dalal P, Bhattacharjee, Vairale J, Bhat P. Mumbai stroke registry (2005-6)-Surveillance using WHO STEPS stroke instrument-challenges and opportunities. *JAPI* 2008; 56: 675-79
- [6] Zeisel, SH. Choline: critical role during fetal development and dietary requirements in adults. *Annu. Rev. Nutr.* 2006. 26:229-50.
- [7] Steven H. Zeisel. Review Nutritional Importance of Choline for Brain Development. *Journal of the American College of Nutrition*.2004; Vol. 23, No. 6, 621S-626S.
- [8] Zhaoyu Li and Dennis E Vance. Thematic Review Series: Phosphatidylcholine and Choline homeostasis. *J of Lipid Research* 2008 Vol 49 1187-1194
- [9] Blusztajn, J.K. and R.J. Wurtman, Choline and cholinergic neurons. *Science*, 1983. 221(4611): p. 614-20.
- [10] Klein, J., Membrane breakdown in acute and chronic neurodegeneration: focus on choline-containing phospholipids. *J Neural Transm*, 2000. 107(8-9): p. 1027-63.
- [11] Wurtman RJ- Choline metabolism as a basis for the selective vulnerability of cholinergic neurons. *Trends in Neurosciences*, 1992;15(4):117-122.
- [12] Blusztajn J K, P G Holbrook, M Lakher, M Liscovitch, J C Maire, C Mauron, U I Richardson, M Tacconi, R J Wurtman - "Autocannibalism" of membrane choline-phospholipids: physiology and pathology. *Psychopharmacology bulletin* 1986; 22(3):781-6.
- [13] Adibhatla RM, Hatcher J F, Dempsey R J.- Citicoline: neuroprotective mechanisms in cerebral ischemia. *J Neurochem* 2002 Jan;80(1):12-23.
- [14] Innis SM –Dietary omega 3 fatty acids and the developing brain. *Brain Res* 2008; 1237:35-43
- [15] Mills JD et al. Dietary supplementation with the omega-3 fatty acid docosahexaenoic acid in traumatic brain injury. *Neurosurgery* 2011 Feb;68(2):474-81.
- [16] Abhishek Desai, Karl Kevala, Hee-Yong Kim., Depletion of Brain Docosahexaenoic Acid Impairs Recovery from Traumatic Brain Injury. *PLOS ONE* 2014 January | Volume 9 | Issue 1 | e86472
- [17] Kim, S.K., K.O. Cho, and S.Y. Kim, White Matter Damage and Hippocampal Neurodegeneration Induced by Permanent Bilateral Occlusion of Common Carotid Artery in the Rat: Comparison between Wistar and Sprague-Dawley Strain. *Korean J Physiol Pharmacol*, 2008. 12(3): p. 89-94.
- [18] Farkas, E., P.G. Luiten, and F. Bari, Permanent, bilateral common carotid artery occlusion in the rat: a model for chronic cerebral hypoperfusion-related neurodegenerative diseases. *Brain Res Rev*, 2007. 54(1): p. 162-80.
- [19] Alexander G. N, Lidija R.Pavle RA and Galyna GS., Structural Features of Ischemic Damage in the Hippocampus. *The Anatomical Record* 292:1914-1921 (2009)
- [20] Hsu, M., et al., Short-term and long-term changes in the post ischemic hippocampus. *Ann N Y Acad Sci*, 1994. 743: p. 121-39; discussion 139-40.
- [21] Johansen, F.F., Interneurons in rat hippocampus after cerebral ischemia. Morphometric, functional and therapeutic investigations. *Acta Neurol Scand Suppl*, 1993. 150: p. 1-32.
- [22] Bendel, O., et al., Reappearance of hippocampal CA1 neurons after ischemia is associated with recovery of learning and memory. *J Cereb Blood Flow Metab*, 2005. 25(12): p. 1586-95.
- [23] Yagita, Y., et al., Neurogenesis by Progenitor Cells in the Ischemic Adult Rat Hippocampus. *Stroke*, 2001. 32(8): p. 1890-1896.
- [24] Vivien Chevalyere and Steven A. Siegelbaum, Strong CA2 Pyramidal Neuron Synapses Define a Powerful Disynaptic Cortico-Hippocampal Loop. *Neuron*. 2010 May 27; 66(4): 560-572. doi:10.1016/j.neuron.2010.04.013.
- [25] Grieb, P., et al., CDP-choline, but not cytidine, protects hippocampal CA1 neurones in the gerbil following transient forebrain ischaemia. *Folia Neuropathol*, 2001. 39(3): p. 141-5.
- [26] Dempsey, R.J. and V.L. Raghavendra Rao, Cytidinediphosphocholine treatment to decrease traumatic brain injury-induced hippocampal neuronal death, cortical contusion volume, and neurological dysfunction in rats. *J Neurosurg*, 2003. 98(4): p. 867-73.
- [27] Wurtman, R.J., Cansev, M., Sakamoto, T., Ulus, I.H.- 2008 Administration of docosahexaenoic acid, uridine and choline increases levels of synaptic membranes and dendritic spines in rodent brain. *World Review of Nutrition and Dietetics* Karger, Basel, 2008; Vol. 99, p. S153-S168.
- [28] Bas, O., et al., The protective effect of fish n-3 fatty acids on cerebral ischemia in rat hippocampus. *Neurochem Int*, 2007. 50(3): p. 548-54.
- [29] Cao, D.H., et al., Protective effect of chronic ethyl docosahexaenoate administration on brain injury in ischemic gerbils. *Pharmacol Biochem Behav*, 2004. 79(4): p. 651-9.
- [30] Allyson West et al .Choline intake influences phosphatidylcholine DHA enrichment in nonpregnant women but not in pregnant women in the third trimester *Am J of Clinical Nutrition* 2013 doi: 10.3945/ajcn.112.050211
- [31] daCosta KA, Rai KS, Craciunescu CN, Parikh K, Mehedint MG, Sanders LM, McLean-Pottinger A, Zeisel SH. Dietary Docosahexaenoic Acid Supplementation Modulates Hippocampal Development in the Pent-/- Mouse. *The Journal of Biological Chemistry*.2010; 285(2)1008-1015.
- [32] Yagita, Y., et al., Neurogenesis by Progenitor Cells in the Ischemic Adult Rat Hippocampus. *Stroke*, 2001. 32(8): p. 1890-1896.
- [33] Lukiw, W.J., et al., A role for docosahexaenoic acid-derived neuroprotectin D1 in neural cell survival and Alzheimer disease. *J Clin Invest*, 2005. 115(10): p. 2774-83.